

Case Series

Pereira Suture: an Alternative Compression Suture to Treat Uterine Atony

Jahitan Pereira: Jahitan Kompresi Alternatif untuk Penanganan Atonia Uteri

Agung B Setiyono¹, Alamsyah Aziz², Agus Sulistyono³, Johannes C Mose²

¹Department of Obstetrics and Gynecology/
Temanggung General Hospital, Central Java

²Department of Obstetrics and Gynecology
Faculty of Medicine, University of Padjajaran/
Dr. Hasan Sadikin Hospital
Bandung

³Department of Obstetrics and Gynecology
Faculty of Medicine, University of Airlangga/
Dr. Soetomo Hospital
Surabaya

Abstract

Objective: To evaluate the use of Pereira suture as a conservative surgical management in postpartum hemorrhage due to uterine atony.

Methods: The study was performed in the Department of Obstetrics and Gynecology, Temanggung General Hospital, Central Java, Indonesia. Data was retrieved retrospectively from medical records, from January 2011 until December 2013.

Results: Pereira suture was done in four cases of uterine atony with failed conservative management, and the procedure was found to be successful in all cases.

Conclusion: Pereira suture is an alternative surgical procedure for the treatment of uterine atony after failed conservative management.

[Indones J Obstet Gynecol 2015; 3: 177-182]

Keywords: pereira suture, postpartum hemorrhage, uterine atony

Abstrak

Tujuan: Untuk mengevaluasi penggunaan jahitan Pereira sebagai metode bedah konservatif pada kasus perdarahan pascasalin yang disebabkan oleh atonia uteri.

Metode: Studi dilakukan di Departemen Obstetri dan Ginekologi RSUD Temanggung, Jawa Tengah, Indonesia. Data diperoleh secara retrospektif dari rekam medis, dari bulan Januari 2011 sampai Desember 2013.

Hasil: Jahitan Pereira dikerjakan pada empat kasus atonia uteri yang gagal manajemen konservatif dan prosedur ini berhasil pada seluruh kasus.

Kesimpulan: Jahitan Pereira merupakan prosedur bedah alternatif untuk penanganan atonia uteri yang gagal manajemen konservatif.

[Maj Obstet Ginekol Indones 2015; 3: 177-182]

Kata kunci: atonia uteri, jahitan Pereira, perdarahan pascasalin

Correspondence: Agung B Setiyono. RSUD Temanggung, Jln. Dr. Sutomo 67, Temanggung, Telephone: 0813-22259739
Email: agung_budis@yahoo.co.id

INTRODUCTION

Postpartum hemorrhage (PPH) constitutes a major cause of maternal mortality, particularly in the developing world, and maternal morbidity in both developed and developing world.¹

PPH is commonly due to the abnormalities of one or a combination of four basic processes. They are referred to as the "4Ts" namely tone (poor uterine contractions), tissue (retained products of conception or blood clots), trauma (to the genital tract) and thrombin (coagulation abnormalities). Uterine atony is the main cause of PPH accounting for about 75-90% of all cases.²

The traditional management of this condition begins with conservative methods such as bimanual uterine compression, medical therapy with uterotonic agents, uterine tamponade with balloons, and occasionally arterial embolisation; the failure of which often mandates surgical intervention. Surgical measures such as ligation of the major pelvic vessels demand a rarely used skill possessed by few registrars. In the event of intractable hemorrhage despite the above measures, hysterectomy is usually the final resort.³

In 2005, Alcides Pereira created a new conservative surgical procedure to treat uterine atony, where a series of transverse and longitudinal sutures were

applied around the uterus and mechanically compress the uterus in an attempt to avoid peripartum hysterectomy. Pereira's original report described seven patients who underwent the Pereira technique for uterine atony, in whom conventional uterotonic agents proved to be ineffective. This technique was successful in preserving the uterus, in all seven cases, and there were no known immediate or long-term complications.⁴

Although this procedure is very effective in treating uterine atony, there are hardly any reports of this procedure being utilised in Indonesia. Our study reviews the cases in which the Pereira suture was used in Temanggung General Hospital to treat uterine atony, and their clinical outcomes are discussed.

METHOD

The study was performed in the Department of Obstetrics and Gynecology, Temanggung General Hospital, Central Java, Indonesia. Data was retrieved retrospectively from medical records, from January 2011 until December 2013.

There were 4 cases PPH due to uterine atony, treated with Pereira suture. This procedure was performed only after uterine atony did not respond with conservative management (uterine massage, bimanual compression and the use of uterotonics, i.e. oxytocin, ergometrine and misoprostol).

The Pereira suture was originally described using multifilament absorbable Vicryl #1, but we used chromic catgut #2. Almost similar to the B-Lynch suture, before performing the Pereira suture, we car-

ried out a test to assess the potential efficacy of this technique. The patient is placed in the Lloyd Davies or semi-lithotomy position (frog leg). An assistant intermittently swabs the vagina to determine the presence and extent of the bleeding. The uterus is then exteriorized and bimanual compression performed. If the bleeding stops on applying such compression, there is a good chance that application of the Pereira suture will succeed.

The Pereira suture consisted of a series of transverse and longitudinal sutures placed around the uterus (Figure 1 and 2).

Placement of the sutures involved a series of bites inserted superficially, taking only the serous membrane and the subserous myometrium without penetrating the uterine cavity (Figure 2). Two or three transverse circular sutures were placed first, starting in the anterior aspect of the uterus, crossing the broad ligament towards the posterior aspect of the uterus, then crossing the opposite broad ligament towards the anterior aspect and tying the suture over the anterior aspect of the uterus. The number of bites in the uterus varied according to the size of the organ. When the suture crossed the broad ligament, it was important to select an avascular area and to be sure that the fallopian tube, the utero-ovarian ligament, and the round ligament were not inside the suture (Figure 1). The last transverse circular suture in the lower uterine segment served as an anchor for two or three longitudinal sutures. Each longitudinal suture started on the dorsal side of the uterus, using a knot to fix it to the lowest circular suture (Figure 3), and ended on the ventral side using another knot attached to the lowest transverse suture (Figure 4).⁴

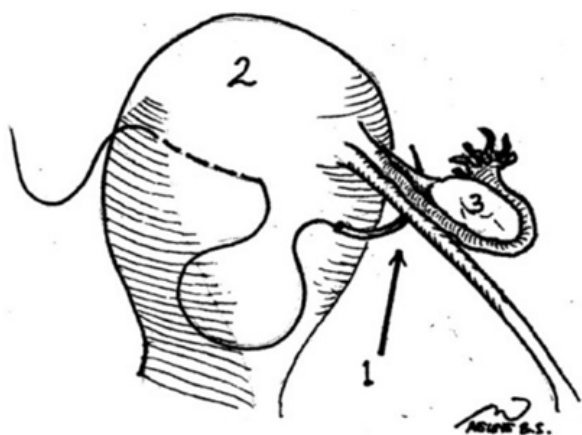


Figure 1. Method of applying transversal sutures. The needle is passed through avascular area of the broad ligament (1), uterus (2), ovary (3).⁴

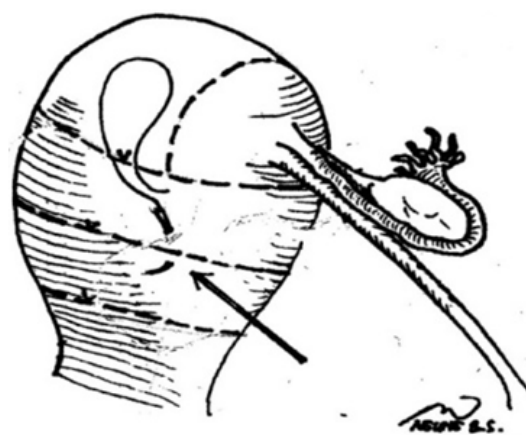


Figure 2. Three transverse circular sutures placed first, followed by longitudinal suture (arrow). All sutures applied with superficial intramyometrial bites.⁴

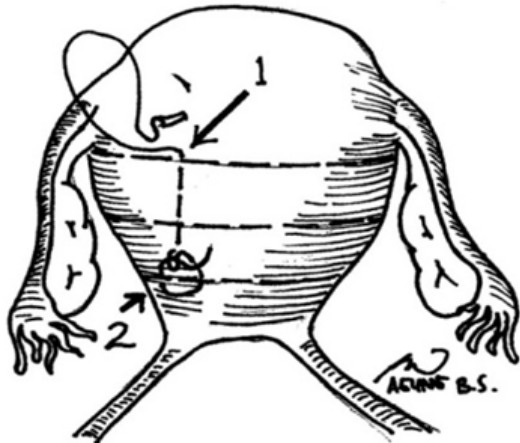


Figure 3. Posterior aspect of the uterus. The first longitudinal suture (1) and first knot to fix longitudinal with transversal sutures (2).⁴

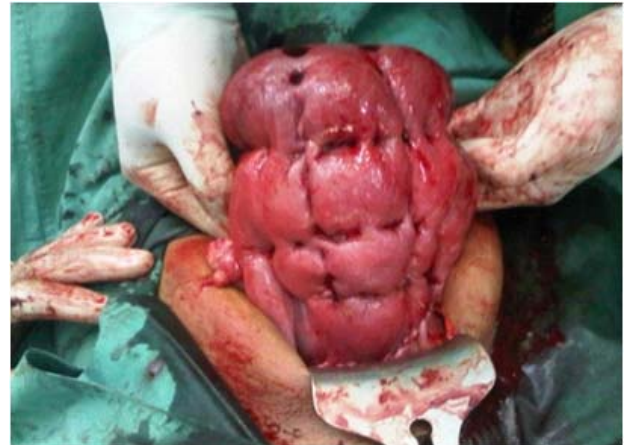

Figure 5. Final result (anterior aspect)

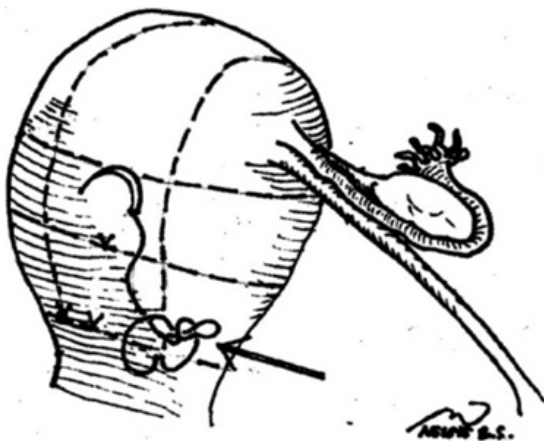


Figure 4. Last knot of longitudinal sutures (arrow).⁴

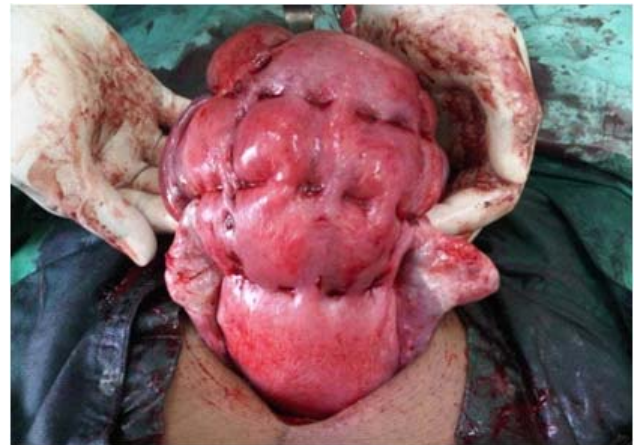

Figure 6. Final result (posterior aspect)

When each myometrial suture was placed, manual compression was applied to the uterus to achieve maximum reduction of uterine volume before tying the suture. The final result of the method is shown in Figure 5 and 6. The mean time required to complete the procedure was 5 minutes (range = 4-7 minutes).⁴

RESULTS

The Pereira suture was attempted in 4 patients from January 2011 to December 2013. The patients' medical history, treatment, and clinical outcomes are summarized in Table 1.

Table 1. di file "tabel pereira case"

DISCUSSION

PPH is a life threatening condition. Fortunately, medical management of PPH is quite successful, and surgical interventions are not needed in the vast majority of the cases. However, when surgical interventions are required, a procedure that is efficient and preserves fertility is preferable.⁵

In 1997, Christopher B-Lynch described an effective surgical technique to treat postpartum bleeding due to uterine atony, known as B-Lynch suture, in five women with PPH. The objective of this technique is to compress the uterus with two longitudinal sutures along its long axis without occluding the uterine arteries.⁶

Variations on this compression technique have been described by some authors, i.e. Hayman⁷, Cho⁸, Nelson and Birch⁹, Ouahba¹⁰, Zheng¹¹, Hackethal¹², Marasinghe¹³, Stanojevic¹⁴, Sulistyono et al¹⁵, Lasso-Budiman¹⁶, Makino-Takeda¹⁷, Mat-subara-Yano¹⁸, Meydanli¹⁹, Bhal¹², Malibary¹², Hwu¹², Tjalma and Jacquemyn.¹²

Although the B-Lynch technique is effective to treat uterine atony, several subsequent publications have reported its complication such as erosion and partial necrosis of the uterine wall.²⁰⁻²³

Another risk with the B-Lynch suture are the risk of infection⁴ and occlusion of the uterine cavity¹¹ due to incision of the uterine wall and penetration of the uterine cavity with the sutures. Pereira's technique offers theoretical advantage to their technique due to the suture not penetrating the endometrial cavity, and being performed without an incision of the uterine wall, thus decreasing the risk of infection and occlusion of the uterine cavity.⁴

Alcides Pereira's original study reported 7 patients with uterine atony and actual postpartum bleeding who were successfully treated by placing compressive sutures around the uterus when conservative management was proven ineffective. The Pereira suture was successful in preserving the uterus, and hence fertility, in all 7 cases, and there were no known immediate or long-term complications.⁴

In our own series, the Pereira technique was performed in 4 women, avoiding the need for hysterectomy in all cases. Each Pereira sutures is made up of a succession of small bites of the uterus, distributing the pressure of the suture more evenly and making compression more effective. The small size of the bites applied to the uterus reduces the risk of a loop

of bowel or the risk of the omentum coming between the uterus and the suture with puerperal involution. Finally, the combination of longitudinal and transverse sutures not only aids compression but also collapses the lumen of ascending branches of the uterine artery, reducing vascular flow and venous bleeding.⁴

Pereira stated that the mean time required to complete the procedure was 5 minutes (range = 4 - 7 minutes),⁴ but in our report the mean time required to complete the procedure was 8.5 minutes (range = 7 - 11 minutes). This implies that we need more cases in order to complete the Pereira procedure within 5 minutes.

CONCLUSION

Our experience implies that Pereira suture is an alternative surgical procedure for the treatment of uterine atony with failed conservative management. However, more cases are needed to achieve a faster timeframe to perform the Pereira suture.

REFERENCES

1. Cameron MJ, Robson SC. Vital statistics: an overview. In: A textbook of PPH. Singapore: Sapiens Publishing; 2006: 17-34
2. Fatima N, Yasmin S, Sadaf J. Combined use of B-Lynch brace suture and uterine packing in primary post partum hemorrhage: saving life and fertility. J Sur Pak Int 2010; 15(3): 144-6.
3. Koh E, Devendra K, Tan LK. B-Lynch suture for the treatment of uterine atony. Sing Med J 2009; 50(7): 693-7.
4. Pereira A, Nunes F, Pedroso S, et al. Compressive uterine sutures to treat postpartum bleeding secondary to uterine atony. Obstet Gynecol 2005; 106(3): 569-72.
5. Al Riyami N, Hui D, Herer E, et al. Uterine compression sutures as an effective treatment for postpartum hemorrhage: case series. Am J Perinatol Reports 2011; 1(1): 47-51.
6. B-Lynch C, Coker A, Lawal AH, et al. The B-Lynch surgical technique for the control of massive postpartum haemorrhage: an alternative to hysterectomy? Five cases reported. Br J Obstet Gynaecol 1997; 104: 372-5.
7. Hayman RG, Arulkumaran S, Steer PJ. Uterine compression sutures: surgical management of postpartum hemorrhage. Obstet Gynecol 2002; 99(3): 502-6.
8. Cho J, Jun H, Lee C. Hemostatic suturing technique for uterine bleeding during cesarean delivery. Obstet Gynecol 2000; 96: 129-31.
9. Nelson GS, Birch C. Compression sutures for uterine atony and hemorrhage following cesarean delivery. Int J Gynecol Obstet 2006; 92: 248-50.
10. Ouahba J, Piketty M, Huel C, et al. Uterine compression sutures for postpartum bleeding with uterine atony. BJOG 2007; 114: 619-22.

11. Zheng J, Xiong X, Ma Q, et al. A new uterine compression suture for postpartum haemorrhage with atony. *BJOG* 2011; 118: 370-4.
12. Hackethal A, Brueggmann D, Oehmke F, et al. Uterine compression U-sutures in primary postpartum hemorrhage after cesarean section: fertility preservation with a simple and effective technique. *Hum Reprod* 2008; 23(1): 74-9.
13. El Senoun GA, Singh M, Mousa HA, et al. Update on the new modalities on the prevention and management of postpartum haemorrhage. *Fetal Mat Med Review* 2011; 22(4): 247-64.
14. Stanojevic D, Stanojevic M, Zamurovic M, et al. Uterine compression suture technique in the management of severe postpartum haemorrhage as an alternative to hysterectomy. *Srp Arh Celok Lek* 2009; 137(11-12): 638-40.
15. Sulistyono A, Gultom ESM, Dachlan EG, et al. Conservative surgical management of postpartum hemorrhage using 'Surabaya method' (modified B-Lynch compression suture). *Indones J Obstet Gynecol* 2010; 34(3): 108-13.
16. Rahman MN, Wiknjosastro GH, Sungkar A, et al. The use of B-Lynch technique and Lasso-Budiman technique to control postpartum hemorrhage in uterine atony. *Indones J Obstet Gynecol* 2010; 34(4): 195-8.
17. Makino S, Tanaka T, Yorifuji T, et al. Double vertical compression sutures: a novel conservative approach to managing post-partum haemorrhage due to placenta praevia and atonic bleeding. *Aust N Z J Obstet Gynaecol* 2012; 52: 290-2.
18. Matsubara S, Yano H, Taneichi A, et al. Uterine compression sutures against impending recurrence of uterine inversion immediately after laparotomy repositioning. *J Obstet Gynaecol Res* 2009; 35: 819-23.
19. Meydanli MM, Turkcuoglu I, Engin-Ustun Y, et al. Meydanli compression suture: new surgical procedure for postpartum haemorrhage due to uterine atony associated with abnormal placental adherence. *J Obstet Gynaecol Res* 2008; 34: 964-70.
20. Joshi VM, Shrivastava M. Partial ischemic necrosis of the uterus following a uterine brace compression suture. *BJOG* 2004; 111: 279-80.
21. Treloar EJ, Anderson RS, Andrews HS, et al. Uterine necrosis following B-Lynch suture for primary postpartum haemorrhage. *BJOG* 2006; 4: 486-8.
22. B-Lynch C. Partial ischemic necrosis of the uterus following a uterine brace compression suture. *BJOG* 2005; 112: 126-7.
23. Grotegut CA, Larsen FW, Jones MR, et al. Erosion of a B-Lynch suture through the uterine wall: a case report. *J Reprod Med* 2004; 49: 849-52.