

Case Report

Complete Atrioventricular Block in Pregnancy***Blok Atrioventrikular Total dalam Kehamilan***Christin Wigin¹, Erdwin R Hasibuan², Soetikno², Yoga Yuniadi², Liva Wijaya¹¹*Department of Obstetrics and Gynecology
Faculty of Medicine University of Indonesia/
Dr. Cipto Mangunkusumo Hospital*²*Harapan Kita Women and Children Hospital
Jakarta***Abstract**

Objective: Complete heart block is an extremely rare and serious complication in pregnancy. Pregnancy outcome in patients with atrioventricular conduction block are unknown, with only a limited number of case reports published. This paper is aimed to report our case and review the available background literature.

Method: Case report.

Case: A twenty-nine years old primigravida in labor presented at 38 weeks of gestation with referral from the primary health center due to bradycardia and her previous history of cardiac problem. Patient has been diagnosed with total atrioventricular block since 2 years ago. Electrocardiography assessment showed the presence of complete heart block. She was then planned for an emergency Caesarean section and later a temporary transvenous pacemaker was implanted.

Conclusion: Management of complete atrioventricular block in pregnancy requires a good team consisting of obstetrician, anesthesiologist and cardiologist.

[Indones J Obstet Gynecol 2015; 1: 56-59]

Keywords: atrioventricular, bradycardia, heart block, pacemaker, pregnancy

Abstrak

Tujuan: Blok atrioventrikular total adalah kasus yang sangat jarang dan merupakan komplikasi yang serius dalam kehamilan. Masih belum jelas bagaimana luaran dari kehamilan dengan blok konduksi atrioventrikular karena sedikitnya jumlah kasus yang pernah dilaporkan. Tulisan ini bertujuan untuk melaporkan kasus kami dan membahas literatur yang ada.

Metode: Laporan kasus.

Kasus: Perempuan dua puluh sembilan tahun datang dalam keadaan inpartu kehamilan pertama pada usia kehamilan 38 minggu dengan rujukan oleh Puskesmas karena bradikardia dan riwayat blok jantung sejak 2 tahun sebelumnya. Pemeriksaan EKG menunjukkan adanya blok atrioventrikular total. Pada akhirnya, tata laksana pasien ini diputuskan untuk seksio sesarea darurat dan kemudian alat pacu jantung sementara dipasang.

Kesimpulan: Tata laksana blok atrioventrikular total dalam kehamilan memerlukan kerjasama yang baik antara dokter spesialis obstetri, anestesi, dan kardiologi.

[Maj Obstet Ginekolog Indones 2015; 1: 56-59]

Kata kunci: alat pacu jantung, blok atrioventrikular, blok jantung, bradikardia, kehamilan

Correspondence: Christin Wigin, Department of Obstetrics and Gynecology, Dr. Cipto Mangunkusumo Hospital. Phone: 081296918877, email: christinwigin@gmail.com

INTRODUCTION

Complete heart block is a rare problem in pregnancy.¹ The prevalence was reported to be 1 in 20,000 pregnancies.² Because it is a rare case, there are still no established guidelines for the management of these patients.³ In general, the approach to the treatment of conduction disturbances and bradycardia in pregnant women is similar to that in the non-pregnant patient. Cardiac and obstetric experience in such patients is limited with only few series or isolated case reports found in the literature. Therefore, treatment strategies of complete atrioventricular block during pregnancy are hampered by the lack of randomized trials in this cohort of women.

CASE ILLUSTRATION

A 29-years old primigravida 38 weeks gestational age presented to our emergency room in the latent phase of labor with complete heart block on 26 March 2014. She only had antenatal care in our outpatient clinic twice. She was referred from the public health center due to bradycardia and a history of cardiac problem. She was diagnosed with total atrioventricular block since two years ago. Patient was advised by the cardiologist to get permanent pacemaker. However, due to financial problems, the patient eventually ceased follow up. She has had no complaints, no history of fainting episodes (Stokes Adam attacks), no chest pain, no exertional dyspnea nor palpitations.

Upon examination, her pulse rate was 42 beats per minute and regular, and BP was 110/60 mm/Hg. There was no cyanosis or edema, and jugular venous pressure was not raised. Examination of cardio-respiratory system revealed no abnormality. Obstetric abdominal examination revealed a singleton fetus in cephalic presentation. Fundal height was 31 cm (clinical estimated fetal weight was 2945 gram). Contraction was strong and regular. Vaginal examination revealed an effaced cervix with 2 cm dilatation. Fetal heart rate was 140 beats per minute. Hemoglobin level was 11.6 g%, while other basic routine laboratory investigations were normal. Electrocardiography assessment showed the presence of complete atrioventricular block with narrow QRS complexes. Echocardiography showed good systolic left ventricular global function with 75% ejection fraction, good diastolic function, mild mitral regurgitation and mild tricuspid regurgitation. Obstetric ultrasound examination revealed no abnormality with normal fetal growth.

She was then planned for an emergency Caesarean section and consulted to the cardiologist. Prior to caesarean section, temporary transvenous pacemaker was implanted through the left subclavian vein and the lead was placed in the right ventricular apex. Caesarean section was conducted with spinal anesthesia, and the patient delivered a baby boy weighing 2700 gram, AS 9/9.

DISCUSSION

Total atrioventricular block (complete heart block) is a disorder of cardiac conduction system where no impulses from the atria reach the ventricles.^{1,4} The block may be at the level of the atrioventricular (AV) node, bundle of his, bundle branches or purkinje system.⁴ When the block is located high in the septum or AV node, typically the QRS complexes are narrow (<0.15 seconds) with a ventricular rate of 40-60x per minute and the heart rate increases in response to exercise, atropine or sympathomimetics.^{2,4,5} Whereas, if the block is located below the bundle of his, the QRS complexes are widened with a ventricular rate less than 40 x/min.^{2,4,5} Our patient most likely had a block at the level of the AV node, since she was hemodynamically stable with narrow QRS complexes.

The etiology of complete heart block may be congenital or acquired.² Acquired atrioventricular conduction blocks may be attributed to fibrosis and sclerosis of the conduction system, ischemic heart disease, the use of negative chronotropic and dromotropic drugs, increased vagal tone, valvular disease, cardiomyopathies, congenitally corrected transposition of the great arteries, electrolyte disturbances, autoimmune diseases, systemic diseases such as sarcoidosis or infectious diseases such as Lyme disease.⁶ Whereas, congenital complete atrioventricular block (CCAVB) is caused by failure of

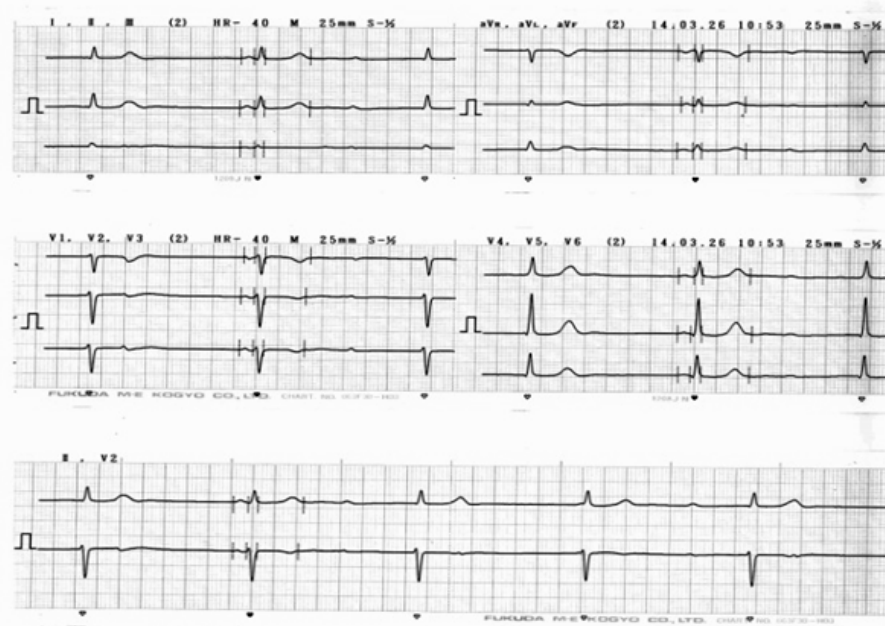


Figure 1. Patient's Electrocardiogram (ECG)

the atrioventricular conduction system that can be diagnosed in utero by fetal echocardiography.⁵ CCAVB may be isolated or combined with other congenital heart diseases.⁵ Thirty percent of CCAVB cases remain undiscovered until adulthood and may therefore present during pregnancy. The etiology is not yet completely understood.¹ Until this publication, we still cannot discover the etiology of complete heart block in our patient.

Fetal growth depends on the maternal supply of nutrients through the placenta into the umbilical circulation.⁷ A decrease in uteroplacental blood flow may cause reduced nutritional supply through the placenta and, consequently, fetal growth restriction (FGR).⁷ It was initially thought that complete heart block will correlate with fetal growth restriction.^{8,9} However in published literature, it has been observed that it does not cause any special problems during pregnancy.^{7,10} It was concluded that there is no significant risk for FGR and preterm delivery in patients with complete atrioventricular block.⁷ Maternal hypertension and preeclampsia have been observed in some cases; however, the incidence was low.⁷ Fetal distress, low Apgar scores, and neonatal acidemia have rarely been observed. In our case, the baby was born in term pregnancy with normal birthweight.⁷

There has been a controversy regarding the value of prophylactic insertion of pacemaker in pregnant patients.^{6,9,11} A pacemaker works by developing small electrical stimulations that helps control the heartbeat. In general, insertion of a pacemaker is indicated in symptomatic patients, patients with widened QRS complexes, or evidence of left atrial enlargement.^{1,5} Asymptomatic patients with chronotropic responsiveness can be managed without insertion of a pacemaker.^{2,5,7,9,12} Hidaka et al demonstrated in six asymptomatic patients with complete atrioventricular block and structurally normal hearts that artificial cardiac pacing was not required.⁶ The work-up to assess chronotropic responsiveness can be achieved through a simple treadmill stress test before and within the first trimester of pregnancy.² Patients in later stages of pregnancy could be assessed with atropine.² Those who are resistant to exercise and atropine indicates they cannot adapt to their changing blood pressure. Increase in heart rate during labor is essential to increase cardiac output and to maintain the hemodynamics. Hence, for a safe delivery, temporary pacemaker insertion was essential, which ideally is done before delivery.⁵ We implanted a

temporary transvenous pacemaker in our patient before cesarean section, as our patient was resistant to increase in her heart rate.

Mode of delivery is actually based on obstetrical indication.⁸ There is no specific reason not to allow labor and vaginal delivery in a woman with complete atrioventricular block. This patient was initially considered to have vaginal delivery due to absence of obstetric indication for cesarean section. During vaginal delivery, there is an increased workload in the cardiovascular system as an increase in cardiac output was needed. In normal labor without epidural anesthesia, a 12% increase in the basal cardiac output is observed between contractions during the first stage of labor.⁷ Furthermore, cardiac output increase progressively as labor advances, reaching an estimated 34% increase at full cervical dilatation.⁷ Since most complete heart block patients cannot achieve a sufficient increase in heart rate, an increase in cardiac output during pregnancy depends mainly on the increase in stroke volume. It is still unclear whether the hemodynamic status of pregnant women with complete heart block without pacemaker insertion remains stable during labor and after delivery, considering the increase in cardiac workload and acute blood loss that often occurs during this period.⁹ These patients may experience syncope and convulsions caused by slowing of the heart rate during valsalva maneuver at the second stage of labor.^{1,5,8,9} Few patients with heart block may have sudden cardiac death for which there are no predictors.⁵ Continuous rhythm monitoring, effective analgesia, shortening the second phase of labor by using forceps and presence of cardiologist during labor is needed if vaginal delivery is preferred.^{1,2,7} Considering all these factors, patient was decided to undergo cesarean section with temporary transvenous pacemaker insertion prior to the operation. Postpartum evaluation should be performed to assess the cardiac function and the need of permanent pacemaker.

CONCLUSION

To manage patients with complete atrioventricular block in pregnancy requires a good team consisting of obstetrician, anesthesiologist and cardiologist. Maternal complication is rare in asymptomatic complete atrioventricular block, even without pacing. Vaginal delivery is not contraindicated in patients with complete atrioventricular block. Fur-

thermore, pregnant patients with complete heart block already using pacemaker can be considered as low risk.

REFERENCES

1. Monem A, Chohan U, Ali M. Epidural anaesthesia during labour for a patient with congenital complete heart block: a case report *J Pak Med Assoc* 2007; 57(11): 565-6.
2. Azarisman S, Fahm L, Huda AN, et al. Emergent caesarean section in parturient with congenital complete atrioventricular block. *JRSM Short Rep* 2010; 1(6): 50.
3. Dalvi B, Chaudhuri A, Kulkarni H, et al. Therapeutic guidelines for congenital complete heart block presenting in pregnancy. *Obstet Gynecol* 1992; 5: 802-4.
4. Ufberg JW, Clark JS. Bradydysrhythmias and atrioventricular conduction blocks. *Emerg Med Clin N Am* 2006; 24: 1-9.
5. Kumar AU, Sripriya R, Parthasarathy S, et al. Congenital complete heart block and spinal anaesthesia for caesarean section. *Ind J Anaes* 2012; 56(1): 72-4.
6. Sharma JB, Malhotra M, Pundir P. Successful pregnancy outcome with cardiac pacemaker after complete heart block. *International J Gynecol Obstet* 2000; 68(2): 145-6.
7. Hidaka N, Chiba Y, Fukushima K, et al. Pregnant women with complete atrioventricular block: perinatal risks and review of management. *Pacing Clin Electrophysiol* 2011; 34(9): 1161-76.
8. Suri V, Keepanasseril A, Aggarwal N, et al. Maternal complete heart block in pregnancy: analysis of four cases and review of management. *J Obstet Gynaecol Res* 2009; 35(3): 434-7.
9. Mehta S, Goswami D, Tempe A. Successful pregnancy outcome in a patient with complete heart block. *J Postgrad Med.* 2003; 49: 98.
10. Bouvrain Y, Kpodonu J, Butruille C, et al. Pregnancy in women with atrioventricular block. 13 cases. *Nouv Presse Med* 1976; 5: 2141-3.
11. Thaman R, Curtis S, Faganello G, et al. Cardiac outcome of pregnancy in women with a pacemaker and women with untreated atrioventricular conduction block. *Europace* 2011; 13: 859-63.
12. Modi M, Butala B, Shah VR. Anaesthetic management of an unusual case of complete heart block for LSCS. *Ind J Anaes* 2006; 50(1): 43-4.