

**Case Series****Spontaneous Uterine Rupture in Placenta Accreta Spectrum****Isharyah Sunarno<sup>1</sup>, Deviana Soraya Riu<sup>1</sup>, Andi Adil<sup>2</sup>, Rachmawati Muhiddin<sup>3</sup>, Juanita<sup>4</sup>**<sup>1</sup>*Department of Obstetrics and Gynecology*<sup>2</sup>*Department of Anesthesiology*<sup>3</sup>*Department of Clinical Pathology*<sup>4</sup>*Department of Anatomical Pathology**Faculty of Medicine Universitas Hasanuddin  
Makassar***Abstract**

**Objective:** To present four cases of grade 3a PAS and their associated maternal and neonatal outcomes related to Spontaneous Uterine Rupture (SUR).

**Methods:** Case series

**Case:** Four cases of SUR associated with FIGO 3A PAS were managed at Wahidin Sudirohusodo Hospital, a tertiary healthcare center in Makassar, Indonesia. All patients were multigravida with prior cesarean sections and presented at preterm gestational ages. Two cases were diagnosed before surgery, with patients in hypovolemic shock and fetal demise, while the other two ruptures occurred during laparotomy with live neonate deliveries. Emergency surgical management, including classical cesarean section and supracervical hysterectomy, was performed, with all mothers discharged in stable condition. This highlights the importance of early recognition and timely intervention in managing PAS-related uterine rupture.

**Conclusion:** SUR in PAS cases is associated with increased maternal morbidity as well as neonatal mortality and morbidity.

**Keywords:** cesarean section, classical cesarean section, placenta accreta spectrum, spontaneous uterine rupture, supracervical hysterectomy.

**Correspondence author.** Isharyah Sunarno. Department of Obstetrics and Gynecology,  
Faculty of Medicine Universitas Hasanuddin, Makassar,  
Email: isharyahsunarno@gmail.com. Telp: +62811461814

**INTRODUCTION**

Uterine rupture is a rare but serious obstetric complication that poses life-threatening risks to both the mother and the fetus. One of the key causes of uterine rupture is Placenta Accreta Spectrum (PAS), a condition where the placenta abnormally attaches to the uterine wall, often leading to uterine rupture. Placenta percreta, a severe form of PAS, can easily be overlooked in clinical practice, but it remains a significant contributor to uterine rupture, which can result in potentially fatal outcomes for both mother and fetus. The incidence of PAS has increased in recent years, largely due to rising cesarean section rates, highlighting the growing need for awareness and early diagnosis. Clinical management of uterine rupture and PAS

requires a multidisciplinary approach, involving obstetricians, anesthesiologists, and surgeons to handle the complexities and risks. Special counseling is crucial for patients with previous cesarean sections or uterine rupture, emphasizing the importance of regular antenatal care and institutional delivery in future pregnancies to prevent complications. Additionally, all deliveries should be classified according to Robson's classification, which helps identify the causes of cesarean sections and guides efforts to reduce unnecessary primary C-section rates. This case series addresses the gap in current literature regarding PAS-related uterine rupture and highlights the importance of early detection and comprehensive care.<sup>1,2</sup>

A study conducted in 96 hospitals across 24 of China's 34 provinces, autonomous regions, and

municipalities, analyzing 74,180 cases from 2015 to 2016, reported an overall incidence of uterine rupture at 0.18% (95% CI: 0.05%–0.23%).<sup>3</sup> Another study reported uterine rupture in 220 patients, corresponding to an incidence rate of 12.1 per 1,000 cases of Placenta Accreta Spectrum (PAS). Of these, 110 cases (6.1 per 1,000) occurred as pre-labor ruptures, while the remaining 110 cases (6.1 per 1,000) took place during labor. Patients with placenta percreta faced a fourfold higher risk of pre-labor uterine rupture compared to those with placenta accreta.<sup>4</sup> A prospective observational study highlighted uterine rupture as a significant and serious obstetric complication.<sup>5</sup>

Based on this background, we present four cases of PAS with Spontaneous Uterine Rupture (SUR) including their management and maternal and neonatal outcomes. Because SUR in PAS is a rare condition, its procedure management solely relies on intraoperative conditions and the operator's judgment. The case reports we present

can serve as a reference in the management and outcomes of maternal and neonatal cases. Further research using methods with higher scientific value is needed to design standardized guidelines.

The study received approval from the Ethics Committee of the Faculty of Medicine, Hasanuddin University (No. 1073/UN4.6.4.5.31/PP36/2024).

CASE

We presented four cases of SUR in PAS patients that occurred at Wahidin Sudirohusodo Hospital a tertiary healthcare and teaching hospital. As a referral center, the majority of patients treated at this institution are referral cases, including the four cases reported here, all of which were referrals. Table 1 illustrates the general characteristics and neonatal outcomes of the four cases we reported.

Table 1. The Characteristics of each Case

Characteristic	Case #01	Case #02	Case #03	Case #04
Year of Occurrence	2021	2022	2023	2024
Parity	G4P2A1	G4P3A0	G2P1A0	G3P2A0
Maternal Age	36 yo	36 yo	27 yo	27 yo
Gestational Age	33-34 wks	26-27 wks	34-35 wks	34-35 wks
Diagnosis	SUR	SUR	SUR + complete UR	SUR
IO Bleeding (ml)	6000	3000	3000	6000
Surgical Procedure	Classical CS + Supracervical hysterectomy	Classical CS + Supracervical hysterectomy	Classical CS + Total Abdominal Hysterectomy	Classical CS + Supracervical hysterectomy
LOS (Day)	6	8	15	9
Neonates	IUFD	IUFD	ALIVE	ALIVE

SUR : spontaneous uterine rupture;  
UR : uterine rupture;  
IO : intraoperative;  
CS : cesarean section  
LOS : length of stay;  
IUFD : intrauterine fetal death.

All cases involved patients with a history of CS in prior deliveries. A study revealed a strong correlation between a history of Cesarean Sections (CS) and the occurrence of PAS. Notably, 50.0% of patients with two prior CS deliveries developed PAS, compared to just 11.1% of those with three prior CS deliveries. These findings underscore a significant correlation between CS history and the likelihood of PAS.<sup>6</sup>

The four cases occurred at preterm gestational ages, spanning the late second trimester and the third trimester. A study indicated that

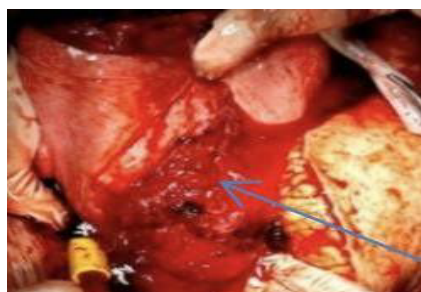
pregnancies following a previous mid-trimester uterine rupture are associated with an increased risk of both PAS and uterine rupture. The results reinforce the need for heightened clinical vigilance in managing subsequent pregnancies in such cases.<sup>7</sup>

In case #03, there were two instances of uterine rupture: a spontaneous rupture in the anterior wall and a complete rupture in the posterior wall extending from the lower uterus to the cervix, identified as an unscarred uterine rupture. A cohort study involving 247 cases of

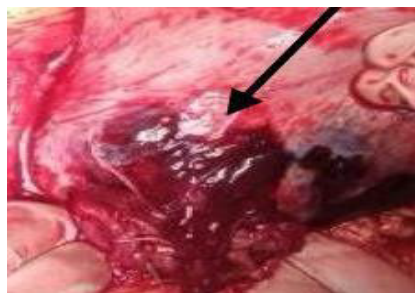uterine rupture found that ruptures in unscarred uteri predominantly occurred outside the lower uterine segment and were more likely to extend beyond the cervix compared to ruptures in scarred uteri.<sup>8</sup>

Various classifications of placenta accreta spectrum (PAS) have been established, including the FIGO classification, which integrates both clinical and histological criteria. Another system, the intrauterine topographic classification, categorizes PAS into five types based on intraoperative assessment. According to the FIGO classification, the four cases in our series are categorized as Grade 3: abnormally invasive placenta (percreta), specifically Grade 3a, which is limited to the uterine serosa.<sup>9</sup> The clinical criteria

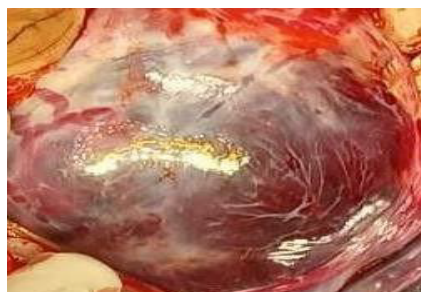observed during laparotomy include abnormal macroscopic findings on the uterine serosal surface, with placental tissue visibly invading through the surface of the uterus. Importantly, there is no invasion into other organs, including the posterior wall of the bladder, and a clear surgical plane can be identified between the bladder and uterus. Histologically, hysterectomy specimens demonstrate villous tissue located within or breaching the uterine serosa. Meanwhile, when adjusted according to intraoperative topographical classification, our four cases classified as type 3: lower anterior.<sup>10,11</sup> Figure 1 illustrates the intraoperative conditions of cases 1 through 4.



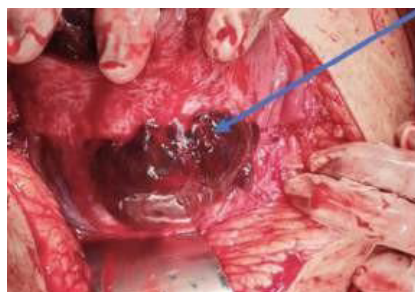
Case #1



Case #2



Case #3



Case #4

**Figure 1.** SUR in 4 cases of PAS. In cases (A), (B), and (C), SUR had already occurred before laparotomy; whereas in case (D), SUR occurred during laparotomy, and the image was taken a few seconds before the rupture happened.

## CASE

As part of the preoperative preparation, all patients received an ultrasound (US) examination to identify the placental location and PAS markers. Comprehensive ultrasound screening for Cesarean Scar Pregnancy (CSP) / PAS should be broadly accessible, with a focus on assessing risk factors and evaluating placental positioning.<sup>12</sup>

For surgical management, a classic CS was selected as the approach method for delivering the baby for PAS cases, as it involves making the uterine incision away from the hypervascularized PAS area. A classical uterine incision was performed to bypass the area with an abnormal

vascular pattern.<sup>13</sup>

A supracervical hysterectomy was performed with the placenta left in situ by securing the umbilical cord and subsequently closing the uterine wall. This technique is designed to minimize blood loss. To achieve this, the uterine wall should be closed before proceeding with the hysterectomy, and the procedure should be performed while keeping the placenta intact.<sup>13</sup>

Massive bleeding in obstetrics is defined as the need for more than 10 units of blood within 24 hours, the transfusion of four units of RBCs within 4 hours with active bleeding exceeding 150 mL/min, the use of more than 8 units of RBCs postpartum, or hemorrhage exceeding 1500 mL

with signs of anemia or hemodynamic instability. It represents a life-threatening condition requiring immediate, coordinated intervention from obstetrics, anesthesia, and blood bank teams. Management may include cryoprecipitate for low fibrinogen levels, early administration of FFP or FDP, tranexamic acid, and consideration of cell salvage. In obstetric cases, massive bleeding is characterized by the need for more than 10 units of blood within 24 hours, the transfusion of four units of red blood cells (RBCs) within 4 hours alongside active bleeding at a rate exceeding 150 mL/min, the use of more than 8 units of RBCs within 24 hours postpartum, the administration of three units of RBCs over 60 minutes, or postpartum hemorrhage exceeding 1500 mL, accompanied by clinical signs of anemia or hemodynamic instability.<sup>14,15</sup> Massive blood transfusion represents a critical, life-threatening condition that involves the rapid delivery of significant volumes of blood products, signaling severe obstetric hemorrhage. Effective management necessitates close collaboration between the obstetric, anesthesia, and blood bank teams. If fibrinogen levels drop below 2 g/L, replacement with cryoprecipitate is essential. Additionally, the early administration of Fresh Frozen Plasma (FFP) or Fibrinogen Degradation Products (FDP) before packed red blood cells (PRBCs) may be required. A 1 g dose of tranexamic acid is typically given as an initial intervention, and the use of cell salvage may also be considered. Massive transfusions can disrupt coagulation processes, alter serum biochemistry, affect acid-base balance, and impair temperature regulation. The interplay of hypothermia, acidosis, and coagulopathy can create a vicious cycle, leading to a progressive and often irreversible decline toward death.<sup>16</sup>

Enhancing the accuracy of prenatal diagnosis, particularly in distinguishing between abnormally invasive placenta and abnormally adherent placenta, is crucial for effective management. Histopathological confirmation remains the gold standard for diagnosing PAS, and perinatal pathologists should be integral members of the multidisciplinary team responsible for managing PAS cases. In our institution, the histopathological findings for PAS cases are classified according to the FIGO system. Grade 1 refers to abnormally adherent placenta, such as placenta adherenta or creta. In these cases, microscopic examination of placental bed samples from hysterectomy specimens reveals extended areas of absent decidua between villous

tissue and the myometrium, with placental villi attached directly to the superficial myometrium. Grade 2 indicates abnormally invasive placenta, or increta, characterized by the presence of placental villi within the muscular fibers and occasionally within the lumen of deep uterine vasculature, including radial or arcuate arteries. Grade 3 encompasses abnormally invasive placenta classified as percreta. This grade is further subdivided into three categories. Grade 3a is limited to the uterine serosa, where villous tissue is found within or breaching the serosal layer. Grade 3b involves urinary bladder invasion, with villous tissue breaching the uterine serosa and infiltrating the bladder wall or urothelium. Grade 3c includes cases with invasion of other pelvic tissues or organs, where villous tissue breaches the uterine serosa and extends into adjacent pelvic structures, with or without concurrent bladder involvement.<sup>9,17</sup>

## DISCUSSION

In our case series, two patients experienced hypovolemic shock and IUFD, highlighting the importance of early referral and prompt diagnosis. The rising incidence of CS has contributed to an increased number of PAS cases, with life-threatening complications often arising early in pregnancy. Patients with a history of CS are at higher risk and require close monitoring. Early diagnosis of PAS is critical for effective management and reducing maternal risks, emphasizing the need for timely detection and intervention, even as early as the first trimester.<sup>18</sup> Early hospitalization for high-risk patients can help with early diagnosis and treatment. For women with reproductive needs, careful management of surgeries, proper suturing techniques, guidance on recovery, and close monitoring during labor are crucial. Proper handling of labor, knowing when surgical assistance is needed, and thorough checks during procedures (e.g., ensuring the integrity of the uterine wall) are also important. Regardless of risk factors, healthcare providers must stay alert for signs of uterine rupture, act quickly when it occurs, and have trained response teams ready. These measures can improve outcomes for both mother and baby.<sup>19,20</sup>

All PAS patients in our hospital received post-operative care in the ICU, as did the four cases we reported. Hemodynamic stability was closely monitored in the ICU, particularly due to the need for massive blood transfusions in these cases. In



cases of massive obstetric hemorrhage, a major cause of maternal mortality, combining surgical procedures such as compression sutures, arterial ligation, or hysterectomy with extensive blood transfusions can be lifesaving. However, while these surgical measures address the immediate issues, blood transfusions, especially in large volumes, can lead to additional complications. Intraoperative blood transfusions during CS have been associated with increased postoperative inflammation, longer hospital stays, and a higher risk of complications compared to patients who did not receive transfusions. As in the four cases we reported, all had a LOS ranging from 6 to 15 days. Starting blood transfusions early, while the body is still compensating, is crucial to prevent further blood loss and serious clotting problems. Effective planning for blood transfusions and early identification of high-risk pregnancies are key to improving patient outcomes and reducing complications.<sup>14,21</sup> A team of specialists from different medical fields is needed to ensure the mother's safety. Working together helps reduce blood loss and other complications. Regular evaluations within the team can improve surgical procedures and outcomes over time. Clear referral systems to PAS-specialized centers should be established for quick assessment and diagnosis of high-risk cases. Trained healthcare providers should evaluate these pregnancies. Efforts should focus on identifying the type of PAS during pregnancy to aid in surgical planning, which should be done at specialized centers equipped to handle PAS cases.<sup>12,22</sup>

If PAS is suspected during pregnancy, even in a uterus without scars, the possibility of uterine rupture, though rare, should be considered if concerning clinical signs appear. Complete and segmento-corporeal uterine lesions are strongly associated with perinatal death, likely because these lesions cause severe bleeding, which can quickly harm the baby. Maternal antepartum hemorrhage is a major risk factor for perinatal death. In developing countries, the high rate of stillbirths is often due to delays in diagnosis and treatment, as many patients arrive at the hospital after the rupture. Since uterine rupture can recur after a mid-trimester rupture, it is crucial to carefully plan the timing of delivery. Enhancing emergency medical access and ensuring low-income women receive necessary obstetric care are essential to reducing these risks.<sup>7,19,23,24</sup>

Preventing and managing uterine rupture requires teamwork from policymakers, healthcare

providers, and the community. Key steps include improving prenatal care, promoting family planning, and training healthcare workers regularly. Quick access to medical transport is also vital to avoid delays in treatment. Good prenatal care is essential, including tracking surgical history. Women should be assessed for risks, high-risk factors closely monitored, and timely referrals made when necessary.<sup>19,20</sup>

The strength of this case report lies in our success in compiling 4 cases of SUR in PAS, a rare occurrence that required a lengthy observation period (from 2021 to 2024). This effort was undertaken to study the management of such cases, with the aim of providing a reference for future SUR cases in PAS. The limitations of our report include the inability to establish a clear link between SUR in PAS cases and successful management due to the small sample size in this case series. Furthermore, intraoperative decisions are largely influenced empirically by the surgical team's experience and judgment.

#### **ACKNOWLEDGEMENT**

We would like to acknowledge Wahidin Sudirohusodo Hospital for its contribution in providing technical assistance and materials in the form of data for the completion of this case report.

#### **CONFLICT of INTEREST**

The authors declare no conflict of interest.

#### **CONCLUSION**

In conclusion, this case series of four patients with SUR associated with PAS emphasizes the critical need for accurate diagnosis, multidisciplinary management, and comprehensive pre-surgical preparation. All mothers survived and were discharged, but their LOS was notably longer and more variable compared to typical post-cesarean recovery. Neonatal outcomes were less favorable, with two cases resulting in IUFD and two neonates surviving. These findings underscore the greater catastrophic impact on fetal outcomes in SUR, particularly in PAS cases, compared to maternal outcomes. Our study highlights the challenges in managing SUR in PAS patients, where early and precise diagnosis is crucial, especially in high-risk individuals with a history of cesarean sections. Timely detection

through ultrasound and vigilant monitoring are essential, with prompt surgical interventions, such as classical cesarean sections and supracervical hysterectomy, critical for optimal management. Coordinated care, particularly in managing severe hemorrhage and applying appropriate surgical techniques, can improve maternal outcomes. However, despite these efforts, fetal survival remains a significant challenge in these complex cases, underscoring the need for further research and refined management strategies in PAS-related uterine rupture. Future research should focus on developing predictive tools for uterine rupture in PAS cases during antenatal care (ANC) using non-invasive methods. These tools and biomarkers could improve early diagnosis and management, potentially enhancing neonatal outcomes. Additionally, creating standardized clinical guidelines for managing SUR in PAS across various healthcare settings will help ensure consistent and high-quality care.

## REFERENCES

- Enebe JT, Ofor II, Okafor II, Placenta percreta causing spontaneous uterine rupture and intrauterine fetal death in an unscored uterus: A case report. *IJSCR*. 2019;65:65–8. <https://doi.org/10.1016/j.ijscr.2019.10.039>
- Vaidya R, KS A, Govindan K, Shah NA. Uterine rupture: A preventable morbidity. *The New Indian J Obstet Gynecol*. 2022 Feb;8(2):273–7. <https://doi.org/10.21276/obgyn.2022.8.2.22>
- Zhan W, Zhu J, Hua X, Ye J, Chen Q, Zhang J. Epidemiology of uterine rupture among pregnant women in China and development of a risk prediction model: Analysis of data from a multicentre, cross-sectional study. *BMJ Open*. 2021 Nov 29;11(11). <http://dx.doi.org/10.1136/bmjopen-2021-054540>
- Komatsu EJ, Matsuzaki S, Mazza GR, Brueggmann D, Mandelbaum RS, Ouzounian MBA JG, et al. Assessment of uterine rupture in placenta accreta spectrum: pre-labor vs in-labor. *AJOG*. 2024 Mar <https://doi.org/10.1016/j.ajog>
- El-Gendy EA, Kamel HH, Mohamed EM, Mousa Mohmamed EM. Evaluation of risk factors and different management forms of uterine rupture cases Evaluation of risk factors and different management forms of uterine rupture cases at Minia University Maternity hospital. (Prospective study). *MJMR*. 2020;31(2):272–6. doi: 10.21608/mjmr.2022.221060
- Yeni CM, Andayani H, Indirayani I, Razali R. The Association between Cesarean Section and Placenta Accreta Hubungan antara Seksio Sesarea dan Plasenta Akreta. *Indones J Obstet Gynecol*. 2022;10(3): 127–32. doi:10.32771/inajog.v10i3.1572
- Matsuzaki S, Takiuchi T, Kanagawa T, Matsuzaki S, Lee M, Maeda M, et al. Maternal and fetal outcomes after prior mid-trimester uterine rupture: A systematic review with our experience. *Medicina (Lithuania)*. 2021 Dec 1;57(12). <https://doi.org/10.3390/medicina57121294>
- Al-Zirqi I, Daltveit AK, Vangen S. Maternal outcome after complete uterine rupture. *Acta Obstet Gynecol Scand*. 2019 Aug 1;98(8):1024–31. doi: 10.1111/aogs.13579.
- Jauniaux E, Ayres-de-Campos D, Langhoff-Roos J, Fox KA, Collins S, Duncombe G, et al. FIGO classification for the clinical diagnosis of placenta accreta spectrum disorders. *IJGO*. 2019;146(1):20–4. DOI: 10.1002/ijgo.12761
- Nieto-Calvache AJ, Aguilera LR. Simulation, A Fundamental Component of Training to Treat Placenta Accreta Spectrum. *Rev Bras Ginecol Obstet*. 2022;44(12):1159–60. <https://doi.org/10.1055/s-0042-1760216>.
- Palacios-Jaraquemada JM, Nieto-Calvache AJ, Aryananda RA, Basanta N. Advantages of individualizing the placenta accreta spectrum management. *Front Reprod Health. Frontiers Media S.A.*; 2023;4:1096175 doi: 10.3389/frph.2022.1096175
- Coutinho CM, Georg AV, Marçal LCA, Nieto-Calvache AJ, Adu-Breda T, D'Antonio F, et al. Placenta Accreta Spectrum Disorders: Current Recommendations from the Perspective of Antenatal Imaging [Internet]. Vol. 45, *Rev Bras Ginecol Obstet*. Georg Thieme Verlag; 2023: 297–302. <https://doi.org/10.1055/s-0043-1770917>.
- Tjokroprawiro BA. Cesarean hysterectomy in a patient with placenta accreta spectrum disorders. *BMJ Case Rep*. 2021;14(3). doi:10.1136/bcr-2021- 242044
- Özgürlük İ, Keskin HL. Incidence of Obstetric Massive Blood Transfusion and Clinical Features: Hospital-Based Study. *New Trend Med Sci*. 2023 Oct 20;4(Supplemental Issue):173–80. Doi:10.56766/ntms.1348308
- Waters JH, Bonnet MP. When and how should I transfuse during obstetric hemorrhage? *International J Obstet Anesth. Churchill Livingstone*. 2021;46 <https://doi.org/10.1016/j.ijoa.2021.102973>
- Krishna HM, Prasad MK, Mitragotri M V., Bipin GI, Gupta D, Sharma R. Recent advances in perioperative blood management. *Indian J Anaesth*. 2023 Jan 1;67(1):130–8. doi: 10.4103/ija.ija\_1043\_22
- Jauniaux E, Zheng W, Yan J. Confirming the diagnosis and classifying placenta accreta spectrum (PAS) disorders: Minutes of 2020 online international workshop on pas in beijing. *MFM*. 2021;3(4):229–31. <http://dx.doi.org/10.1097/FM9.000000000000106>
- Amza M, Loghin MG, Vâlcea DI, Gică N, Conea IM, Gorecki GP, et al. Life-Threatening Obstetrical Emergency: Spontaneous Uterine Rupture Associated with Placenta Percreta in the First Trimester of Pregnancy. *Case Report and Literature Review. Reports*. 2024 Mar 18;7(1):21. <https://doi.org/10.3390/reports7010021>
- Kitenge JN, Mukuku O, Kinenkinda XK, Kakudji PL. Maternal and perinatal outcomes of uterine rupture in Lubumbashi, Democratic Republic of Congo. *CJOG*. 2020 Oct 20;3(2):136–41. doi: 10.29328/journal.cjog.1001067
- Xie J, Lu X, Liu M. Clinical analysis of complete uterine rupture during pregnancy. *BMC Pregnancy Childbirth*. 2024 Dec 1;24(255). doi: 10.29328/journal.cjog.1001067
- Zhou Y, Liu Z, Xu Z. Association of intra-operative red blood cell transfusion on the systemic immune index and recovery in patients undergoing cesarean section: a large propensity score-matched study. *Perioperative Med*. 2024 Oct 8;13(1):100. <https://perioperativemedicinejournal.biomedcentral.com/articles/10.1186/s13741-024-00457-w>

22. Nugraha GBA, Yuliantara EE. Multidisciplinary Approach of Placenta Accreta Spectrum Management to Reduce Blood Loss and Prevent Organ Injury in Referral Center. *Indones J Obstet Gynecol.* 2024 Jul;12(3):137-40. <https://doi.org/10.32771/inajog.v12i3.2098>
23. Nardi E, Seravalli V, Abati I, Castiglione F, Tommaso M Di. Antepartum unscarred uterine rupture caused by placenta percreta: a case report and literature review. *Pathologica.* 2023;115(4):232–6. doi: 10.32074/1591-951X-882
24. Kumara MG, Debelew GT, Ademe BW. Trend, prevalence, and associated factors of uterine rupture at Nekemte Specialized Hospital, Oromia Regional State, Western Ethiopia. *Sci Rep.* 2024 Dec 1;14(1):25722. doi: 10.32074/1591-951X-882