

## Case Report

## Leiomyoma Ablation with Ultrasonography-Guided Radiofrequency: A Report of Four Cases

### *Ablasi Mioma dengan Radiofrekuensi Terpadu Ultrasonografi: Laporan Empat Kasus*

Doddy Sutanto, Ery S. Sevriana, Rukmono Siswishanto, Lydia Olivia, Rahmalina

Department of Obstetrics and Gynecology  
Soerojo Hospital  
Magelang

**Abstract:**

**Objective:** This study aims to report the successful application of transvaginal ultrasound-guided radiofrequency ablation (RFA) as a minimally invasive therapy in four women with symptomatic intramural and subserous leiomyomas using a standard protocol.

**Methods:** A report of four cases.

**Case:** A case report of four patients was conducted at Soerojo Hospital, Magelang, from September 2021 to January 2022. The first case involved a premenopausal woman experiencing pelvic discomfort. The second case underwent curettage after a diagnosis of a blighted ovum; the third case presented with non-cyclic pain and irregular cycles, while the fourth case had a history of 14-year-old infertility and repeated IVF failures. Three out of the four women with leiomyomas in this report experienced heavy menstrual bleeding. No significant side effects or complications occurred during or after the treatment. Uterine leiomyoma size was monitored for one week and three months, showing an average reduction of 56.9%, indicating a significant decrease in myoma volume. Additionally, the reported symptoms showed improvement.

**Conclusion:** Transvaginal ultrasound-guided radiofrequency ablation proves to be an effective and minimally invasive therapy with minor side effects, making it a promising primary choice for leiomyoma treatment.

**Keywords:** leiomyoma, radiofrequency ablation, transvaginal ultrasonography.

**Abstrak**

**Tujuan:** Untuk melaporkan keberhasilan pengaplikasian ablasi radiofrekuensi (ARF) terpadu ultrasonografi transvaginal sebagai terapi minimal invasif pada empat perempuan dengan mioma intramural dan suberosa bergejala dengan menggunakan protokol baku.

**Metode:** Laporan empat kasus.

**Kasus:** Laporan kasus dilakukan di Soerojo Hospital, Magelang dari bulan September 2021 hingga Januari 2022. Kasus pertama adalah seorang perempuan pramenopause dengan keluhan rasa tidak nyaman pada panggul. Pada kasus kedua, pasien menjalani kuretase setelah didiagnosis dengan blighted ovum, kasus ketiga dengan nyeri non-siklus dan siklus haid tidak teratur, dan kasus keempat adalah infertilitas 14 tahun dan kegagalan IVF berulang. Tiga dari empat perempuan pada laporan ini mengalami perdarahan menstruasi yang banyak. Tidak ada efek samping yang berarti atau komplikasi yang terjadi setelah tindakan, dan selama pemantauan. Pemantauan ukuran mioma uteri selama satu minggu dan tiga bulan menunjukkan penurunan rata-rata sebesar 56,9%, menunjukkan penurunan volume mioma yang signifikan. Gejala-gejala yang dilaporkan juga mengalami perbaikan.

**Kesimpulan:** Ablasi radiofrekuensi terpadu ultrasonografi transvaginal merupakan terapi non-invasif yang efektif dengan efek samping minimal, sehingga dapat menjadi pilihan utama untuk terapi mioma uteri.

**Kata kunci:** ablasi radiofrekuensi, mioma, ultrasonografi transvaginal.

**Correspondence author.** Doddy Sutanto. Department Obstetrics and Gynecology.  
Prof. Dr. Soerojo Mental Hospital, Magelang. Email: doddysutanto.soerojohospital@gmail.com

Received: September, 2022 Accepted: June 2023, Published: July, 2023

## INTRODUCTION

Leiomyoma, also known as uterine fibroids, is the most common benign solid pelvic tumor in women, affecting 70-80% of them by the age of 50. About one-third of women develop leiomyoma during their lifetimes.<sup>1</sup> Most leiomyomas are asymptomatic.<sup>2</sup> However, 50% of women who have leiomyoma report relevant symptoms that are frequently associated with fibroids, such as abnormal menstrual bleeding, pain, pressure, infertility, and repeated miscarriages.<sup>3</sup>

Currently, there are available management options suitable for leiomyomas, but there are still unmet needs according to patient preferences.<sup>4</sup> Medication is usually used on a short-term basis and is not effective with long-term use.<sup>5</sup> Data shows that most patients avoid suggested procedures such as hysterectomy, myomectomy, and uterine artery embolization.<sup>6</sup> Minimally invasive management of symptomatic leiomyomas is becoming a popular option as an alternative to traditional surgical resection.<sup>7</sup>

Radiofrequency ablation was developed to offer women a new minimally invasive treatment option for leiomyomas that is effective, safe, and suitable for those who want to preserve their uterus.<sup>6</sup> Radiofrequency ablation has also found wide application in treating tumors in various organs such as the adrenal glands, bones, breasts, kidneys, lungs, liver, and prostate.<sup>8</sup> The first use of radiofrequency ablation for fibroids was reported in 2002.<sup>9</sup> The safety and effectiveness of RFA in reducing the volume and symptoms of leiomyomas have been extensively documented. However, transvaginal ultrasound-guided radiofrequency ablation (RFA) in uterine leiomyomas has not been widely reported in Indonesia. As a result, the data presented in this case report are considered preliminary.

### CASE 1

A 56-year-old para 2 presented with pelvic discomfort and requested the removal of her intrauterine device (IUD). Despite being in the early stages of menopause, she mentioned experiencing regular periods until last year. During her admission, an ultrasound examination incidentally discovered a subserous leiomyoma, measuring 4.6 cm x 4.3 cm with a volume of 44.6 cm<sup>3</sup>, located at the posterior corpus of the uterus. After being informed about the radiofrequency ablation (RFA) procedure, the patient agreed to

undergo it, hoping for immediate shrinkage of the myoma and relief from pelvic discomfort. The RFA procedure, performed under anesthesia, involved targeting an area of 3 cm x 3.3 cm with RFA needles.

At the one-week follow-up, the patient returned for sonography and found that the volume of the leiomyoma had reduced to 38.7 cm<sup>3</sup>, resulting in relief from pelvic discomfort.

At the three-month follow-up, the volume of the myoma had decreased by 45% compared to the initial examination. Currently, the patient's menstruation has stopped, and she has no more complaints.

### CASE 2

A 41-year-old woman with 4-years of marriage, gravida 1, para 0, abortus 1, presented with heavy menstrual bleeding and a history of bleeding after each sexual intercourse. In her obstetric history, she had experienced a prior anembryonic pregnancy one year ago and had undergone laparoscopic myomectomy and cervical polyp removal in 2019. In September 2021, the patient reported a delayed period. Upon admission, sonography revealed an 11-week empty gestational sac and an intramural leiomyoma measuring 7.3 cm x 6.3 cm with a volume of 164.6 cm<sup>3</sup> in the left anterior corpus. The leiomyoma was pushing towards the uterine cavity. After discussing the options, the patient agreed to undergo curettage and radiofrequency ablation (RFA) simultaneously to remove the myoma, with the hope of preserving her uterus for future childbearing. Under anesthesia, a curettage was performed, followed by RFA. The area pierced by the RFA needle measured 2.8 cm x 2.65 cm. After one week of follow-up ultrasonography, the volume of the leiomyoma was found to be 91.9 cm<sup>3</sup>. At the three-month follow-up, the patient returned for sonography, and it was observed that the leiomyoma size had reduced by 85%. Additionally, the heavy menstrual bleeding was significantly alleviated.

### CASE 3

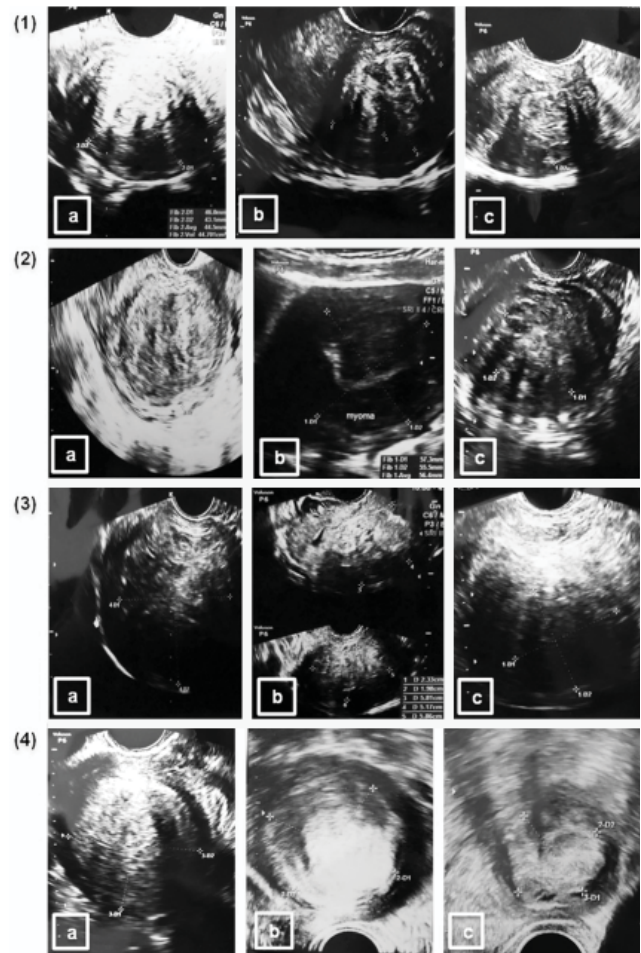
A 31-year-old woman, para 1 abortus 1, reported A 31-year-old woman, presented with complaints of heavy menstrual bleeding, non-cyclic pain, and irregular cycles. The patient had been married for four years, and her child was born three years ago. A sonographic examination

revealed the presence of an intramural leiomyoma in the right fundus, measuring 6.2 cm x 6.2 cm with a volume of 124.7 cm<sup>3</sup>. The patient was informed about the radiofrequency ablation (RFA) method and agreed to undergo the procedure, hoping for immediate shrinkage of the myoma and relief from her symptoms. The RFA procedure was performed under anesthesia, with the RFA needles piercing an area of 3 cm x 2 cm.

At the one-week follow-up, the volume of the myoma had reduced to 73.6 cm<sup>3</sup>, resulting in a significant reduction in menstrual complaints. After three months, a sonography examination revealed that the size of the myoma had further decreased to 4.7 cm x 4.3 cm x 4.8 cm, with a volume of 50.9 cm<sup>3</sup>, representing a 59% reduction. As a result, heavy menstrual bleeding was reduced, and the menstrual cycle became more regular.

#### CASE 4

A 32-year-old woman, P0A0, has been married for 14 years, complained of heavy and prolonged menstruation. She had a family history of leiomyomas and had undergone laparotomy myomectomy three years ago due to multiple leiomyomas. Despite several attempts at in vitro fertilization (IVF) with no success, she plans to undergo IVF again this year. During ultrasonography, two intramural leiomyomas were detected in the corpus, with dimensions of 5.5 cm x 5.4 cm x 5.3 cm and a volume of 82.4 cm<sup>3</sup>, and 4.0 cm x 4.0 cm with a volume of 33.5 cm<sup>3</sup>. The patient was informed about the radiofrequency ablation (RFA) method and agreed to undergo the procedure, hoping for the shrinkage of the leiomyomas and a reduction in symptoms. However, only one myoma was treated, with the RFA needle piercing an area of 3 cm x 3 cm. At the one-week follow-up, the patient returned for a sonographic examination, which showed a reduction in the myoma volume to 65.4 cm<sup>3</sup>. At the three-month follow-up sonographic examination, the myoma size was found to be reduced by 38% compared to the initial admission. Additionally, heavy menstrual bleeding was also reduced.



**Figure 1.** Pelvic ultrasound Case 1 (1), Case 2 (2), Case 3 (3), Case 4 (4) before RFA (a), after 1 week post RFA (b), after 3 months post RFA (c)

There were no adverse events or complications observed in any of the four patients after the procedure and during the observation period. Pelvic examination showed minimal bleeding, with no active bleeding, and the patients reported no complaints of pain. The mean volume reduction at the three-month follow-up was 56.75%.

#### DISCUSSION

Leiomyomas, the most common neoplasms affecting women, are estimated to be clinically present in 25% of women of reproductive age and are estimated to occur in over 70% of women at the onset of menopause. The increased risk of uterine fibroids in premenopausal women is likely attributed to the influence of female sexual hormones that promote fibroid growth. In our case, three of the women were in the reproductive age, while one woman was in the premenopausal state.

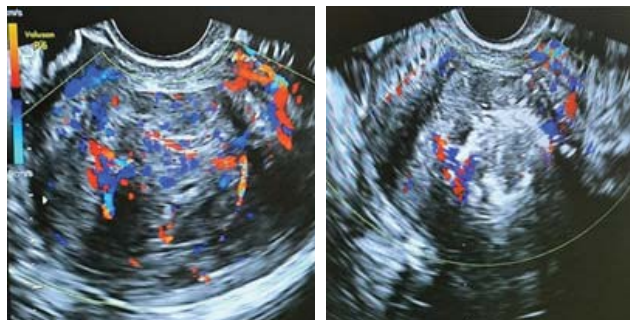
Symptoms caused by leiomyomas vary depending on the number, size, and location



of the tumors. Traditionally, leiomyomas are classified based on their location in the uterus, which includes cervical, submucous, subserous, and intramural leiomyomas. Heavy menstrual bleeding is commonly associated with submucous and intramural leiomyomas, while subserous lesions can lead to pelvic pain. Other symptoms may include non-cyclic pain, painful intercourse, abdominal tightness, or pelvic pressure. In our cases, the myomas were located in the intramural and subserous layers, and the patients presented with symptoms such as profuse menses, pelvic discomfort, pain during intercourse, non-cyclic pain, and irregular cycles.

The presence of submucosal and/or large intramural myomas has also been linked to adverse pregnancy outcomes, such as increased risk for miscarriage.<sup>13</sup> Eventhough, the evidence related to the effect of uterine fibroids on early miscarriages (which comprises anembryonic pregnancies) is debated, researchers believe that endometrium in **areasofanatomicalabnormalitiesmayhaveanaberrantbloodsupplythatisunfavorableforimplantationandcannotsustainthedevelopmentoftheembryo.**<sup>14</sup> In our case, on ultrasound examination of a patient with a blighted ovum 11 weeks pregnant, it was found that the size of the myoma enlarged as the size of the uterus increased during pregnancy. Some previous studies also mentioned that there is an increase in fibroid volume with the largest enlargement occurring in the first trimester and explained human chorionic gonadotropin as an important contributing factor.<sup>15</sup> Then, in the postpartum phase, as the uterus undergoes involution, leiomyomas begin to exhibit vascular degeneration, causing them to diminish due to a lack of nourishment.<sup>16</sup>

In our case, the fourth patient, who had a history of leiomyomas, had been experiencing infertility for 14 years and had undergone repeated in vitro fertilization (IVF) failures. Leiomyomas can be the sole cause of infertility in around 2-3 percent of women. Women with intramural and submucosal leiomyomas that distort the endometrial cavity tend to have lower pregnancy, implantation, and delivery rates in IVF compared to infertile women without leiomyomas. The presence of leiomyomas may influence implantation through various mechanisms, such as increased uterine contractility, dysregulation of cytokines, chronic inflammation, and abnormal vascularization.



**Figure 2.** Vascularization before RFA (left), after RFA (right)

### Procedure of Radiofrequency ablation

Radiofrequency ablation (RFA) has proven to be an effective and safe alternative treatment for uterine leiomyomas, offering the advantage of being minimally invasive. The procedure can be performed via laparoscopy, transcervical, or transvaginal approach, leading to coagulative necrosis of the leiomyomas and subsequent relief of related symptoms. However, a challenge encountered in these case reports is the higher cost associated with RFA, as it is not currently covered by government insurance.

In this case report, the procedure was carried out under total intravenous anesthesia with the presence of an anesthesiologist. Once the patient was sedated, a transvaginal ultrasound probe with attached needle guidance was inserted. Prior to the ablation procedure, the initial preoperative evaluation was conducted to confirm the number, size, and location of the leiomyomas. The volume of the leiomyomas was calculated using the formula:  $\text{volume} = \frac{4}{3}\pi r^3$ , where "r" represents the mean value of the longitudinal, transverse, and anteroposterior radii of the mass.

The device used was an RF generator system type V1000 made in Korea, which consists of an RF generator with an input power frequency of 50/60 Hz and an output radiofrequency of 480000 Hz with a power used of 40-70 atts. The electrode needle was connected to an RF pumping cooling set, which flowed a semi-frozen saline (NaCl) solution, as well as to the RF generator.

The needle electrode was guided under ultrasound to the center of the targeted myoma. The ablation procedure commenced by activating a cooling pump to lower the needle temperature below 15°C. Subsequently, the RF generator was initiated with an automatic protocol, where the power output adjusted automatically based on tissue impedance measurement to maintain stable impedance. Ablation was focused on 60-70% of the entire area of each mass. Three

ablation sessions were performed, each lasting 30 seconds, until the electrode tips in the myoma area turned more hyperechoic on ultrasound images, with the target myolysis temperature set at 60°C. The entire ablation session took approximately 3 minutes to complete. Due to its short procedure time, RFA can be performed within a single day.

### CONCLUSION

Transvaginal ultrasound-guided RFA proves to be a viable and effective option for treating leiomyomas, offering a minimally invasive approach with minimal side effects. However, to validate its safety and long-term clinical success, further studies with extended and standardized follow-up periods are essential in patients with leiomyoma.

### REFERENCES

- Bradley LD, Pasic RP, Miller LE. Clinical Performance of Radiofrequency Ablation for Treatment of Uterine Fibroids: Systematic Review and Meta-Analysis of Prospective Studies. *J Laparoendosc Adv Surg Tech*. 2019 Dec 1;29(12):1507–17.
- Dubuisson J. The current place of mini-invasive surgery in uterine leiomyoma management. *J Gynecol Obstet Hum Reprod*. 2019 Feb 1;48(2):77–81.
- Dolmans MM, Cacciottola L, Donnez J. Conservative Management of Uterine Fibroid-Related Heavy Menstrual Bleeding and Infertility: Time for a Deeper Mechanistic Understanding and an Individualized Approach. *J Clin Med*. 2021 Sep 26;10(19):4389.
- Al-Hendy A, Myers E, Stewart E. Uterine Fibroids: Burden and Unmet Medical Need. *Semin Reprod Med*. 2017 Nov 3;35(06):473–80.
- Chwalisz K, Taylor H. Current and Emerging Medical Treatments for Uterine Fibroids. *Semin Reprod Med*. 2017 Nov 3;35(06):510–22.
- Donnez J, Donnez O, Dolmans MM. The current place of medical therapy in uterine fibroid management. *Best Pract Res Clin Obstet Gynaecol*. 2018 Jan;46:57–65.
- Wang Y, Zhang S, Li C, Li B, Ouyang L. Minimally invasive surgery for uterine fibroids. *Ginekol Pol*. 2020 Mar 31;91(3):149–57.
- Singh S, Repaka R. Temperature-controlled radiofrequency ablation of different tissues using two-compartment models. *Int J Hyperth*. 2017 Feb 17;33(2):122–34.
- Baxter BL, Seaman SJ, Arora C, Kim JH. Radiofrequency ablation methods for uterine sparing fibroid treatment. *Curr Opin Obstet Gynecol*. 2022 Aug;34(4):262–9.
- Stewart E, Cookson C, Gandolfo R, Schulze-Rath R. Epidemiology of uterine fibroids: a systematic review. *BJOG*. 2017; 124(10):1501-12. doi: 10.1111/1471-0528.14640. Epub 2017 May 13
- Heinonen HR, Pasanen A, Heikinheimo O, Tanskanen T, Palin K, Tolvanen J, et al. Multiple clinical characteristics separate MED12-mutation-positive and -negative uterine leiomyomas. *Sci Rep*. 2017 Apr 21;7(1):1015.
- Freytag D, Günther V, Maass N, Alkatout I. Uterine Fibroids and Infertility. *Diagnostics*. 2021 Aug 12;11(8):1455.
- Vlahos NF, Theodoridis TD, Partsinevelos GA. Myomas and Adenomyosis: Impact on Reproductive Outcome. *Biomed Res Int*. 2017;2017:1–14.
- Jackson T, Watkins E. Early pregnancy loss. *J Am Acad Physician Assist*. 2021 Mar;34(3):22–7.
- Sarais V, Cermisoni G, Schimberni M, Alteri A, Papaleo E, Somigliana E, et al. Human Chorionic Gonadotrophin as a Possible Mediator of Leiomyoma Growth during Pregnancy: Molecular Mechanisms. *Int J Mol Sci*. 2017 Sep 20;18(9):2014.
- Tian Y, Wang Q, Wang H, Wu J, Dai Y. Change of uterine leiomyoma size during pregnancy and the influencing factors: A cohort study. *Int J Gynecol Obstet*. 2022 Jun 29;157(3):677–85.