

Case Report**Mosaic Form of Turner Syndrome**

**Abdurahman Laqif^{1,2,4*}, Agung Sari Wijayanti^{1,2,4}, Annang Giri Moelyo^{1,3,4},
Uki Retno Budihastuti^{1,2,4}, Eriana Melinawati^{1,2,4}**

¹*Dr. Moewardi General Hospital*

²*Division of Gynecology Department of Obstetrics and Gynecology*

³*Division of Endocrinology Department of Pediatrics*

⁴*Faculty of Medicine Universitas Sebelas Maret*

Surakarta

Abstract

Objective: To report a case of breast growth disorder in a mosaic form of Turner Syndrome. Turner syndrome is a chromosomal condition characterized by small height and primary ovarian insufficiency that affects one in every 2500 female births. Mosaicism is likely to occur when monosomy X develops in only a few cells during development. The clinical presentation of Turner syndrome mosaicism is atypical, with symptom severity varying based on the number of affected cells. This case discusses issues with secondary sex development, including mild hyperandrogenism, and explores how combination hormonal treatment can aid in enhancing secondary sex development.

Method: Case Report.

Case: A 21-year-old woman presented with chief complaint of the lack of breast enlargement. She exhibited normal genitalia internally and externally and had a regular menstrual cycle. Karyotyping revealed a mosaic pattern of 45, X/46, XX (1 percent/99%) with normal estradiol levels and elevated testosterone levels (indicating mild hyperandrogenism). The patient underwent two cycles of hormone therapy using Ethinyl Estradiol and Drospirenone, resulting in breast growth progression from Tanner stage 1 to Tanner stage 2.

Conclusion: Mosaicism in Turner syndrome is plausible, and the severity of clinical symptoms correlates with the number of defective chromosomes. The presentation of Turner syndrome mosaicism varies, and therapy should be tailored to address specific symptoms. While breast development is observed in some girls with Turner Syndrome, instances of breast growth disorder may occur, involving estrogen activity and estrogen receptor sensitivity. Although the exact cause of impaired breast growth remains unknown, administering estrogen in such cases can improve secondary sexual characteristics.

Keywords: mild hyperandrogenism, mosaicism, turner syndrome.

Correspondence author. Abdurahman Laqif. Department of Obstetrics and Gynecology
Faculty of Medicine Universitas Sebelas Maret. Dr Moewardi Hospital. Surakarta.
Email; a_laqif@staff.uns.ac.id

INTRODUCTION

Turner syndrome (TS), also known as congenital ovarian hypoplastic syndrome, is characterized by a woman's X chromosome being partially or fully absent, resulting in small stature, primary ovarian insufficiency, gonadal dysgenesis, and infertility. This disease affects one out of every 2500 female newborns.^{1,2} Some cases of Turner syndrome are monosomy X (45,X), 5-10% are long arm X duplications (46,X,i(Xq)), and the rest are 45,X mosaicism with one or more extra cells.³ "Classic" Turner syndrome refers to cases in

which the X chromosome is fully absent, whereas "Mosaic" Turner syndrome refers to cases in which the defect only affects the X chromosome of a few cells of the body, with few or no symptoms. The mosaic pattern 45,X/46,XX has the highest frequency of all the mosaic patterns (36%). Turner syndrome mosaicism results in an unusual clinical presentation.^{1,3}

CASE

A 21-year-old woman presented with chief complaint of the lack of breast enlargement, and

her height and weight were 150 cm and 43 kg, respectively. The internal and external genitalia have typical appearances, and menstruation occurs on a regular basis. Without clinical hyperandrogenism, karyotyping revealed 45, X/46, XX (1 percent /99 percent) (Figure 1) with normal estradiol levels and increased testosterone levels (mild hyperandrogenism) without virilization (Table 1).

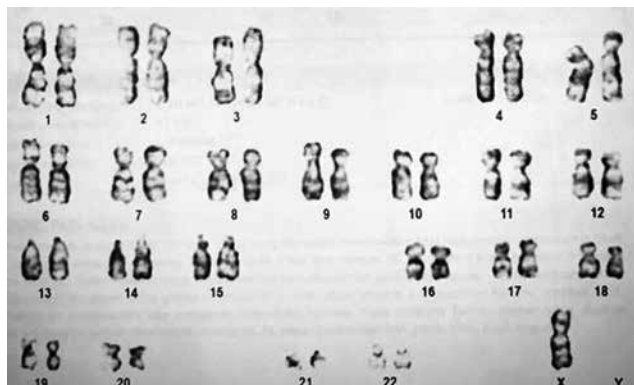


Figure 1. Karyotyping Report

Table 1. Hormone Levels Measured before and after Treatment

| Laboratory Test | before Treatment | after Treatment |
|-----------------|------------------|-----------------|
| Prolactin | 10.48 ng/ml | |
| Estradiol | 153 pg/ml | 62 pg/ml |
| Testosteron | 34.38 ng/dl | 39.29 ng/dl |

At Tanner stage 1, the examination of secondary sex development revealed small, undeveloped breasts and no hair in the armpits. Over the course of two cycles, the patient received hormone therapy comprising a combination of Ethinyl Estradiol and Drospirenone, resulting in breast growth progression from Tanner stage 1 to Tanner stage 2 (Figure 2).

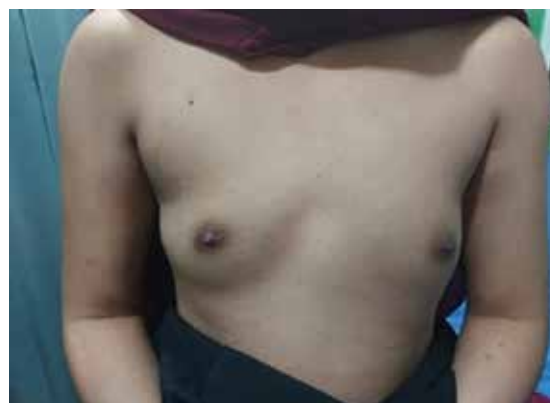
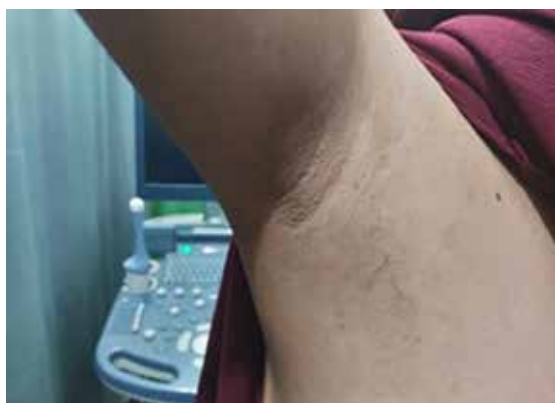
Figure 2. Tanner 2 Secondary Sexual Development Disorder (after therapy)

DISCUSSION

Turner syndrome (TS) is a condition wherein a woman's X chromosome is entirely or partially lost. The incidence of TS occurs in 1 in 2000 to 2500 live-born girls, and it is the only monosomic syndrome in which individuals can survive.⁴

45,X is the traditional karyotype for TS. In a recent research, only 45 percent of individuals had the traditional karyotype; the rest had a mosaic karyotype (45,X/46,XX or 45,X/47,XXX), a karyotype with structural abnormalities on the X chromosome (eg i(Xq) or i(Xp)), or a karyotype with a Y chromosome or chromosomal fragment.²

Short stature, infertility, estrogen deficiency, hypertension, elevated liver enzymes, middle ear infection, micrognathia, bone age retardation, decreased bone mineral content, cubitus valgus,

and underdevelopment during the first postnatal year are the most common physical abnormalities affecting women with TS.^{2,5} Hypothyroidism, diabetes, heart disease, osteoporosis, congenital abnormalities (heart, urinary system, face, neck, ears), neurovascular disease, and liver cirrhosis, as well as colon and rectal cancer, are all considerably more common in women with TS.⁶

The occurrence of two or more lineages of cells with distinct genotypes emerging from a single zygote in a single human is known as genetic mosaicism. Postzygotic mutations cause genetic mosaicism. The zygote is generated when a sperm (23 chromosomes) and an ovum (23 chromosomes) fuse together. The zygote then divides through mitosis to form the full human body. Ideally, all zygotic offspring would possess identical genomes, but this is not always the

case. Mosaicism occurs during one of the phases following the formation of the zygote.⁷

Mosaicism stems from genetic abnormalities occurring in either the germline or somatic cells of the body, such as single nucleotide variations, chromosomal aberrations, copy number variants, among others. It can occur randomly or originate from stem cells. The extent and proportion of cells affected by mosaicism dictate the specific tissue impacted, which may range from non-gonadal tissue only, solely gonadal tissue, to affecting all bodily tissues. The quantity of cells involved dictates the phenotypic expression. Depending on triggering factors, this expression might manifest during pregnancy, after delivery, or even later in life.⁷

The X chromosome may be lost during early embryonic cell division in people with Turner syndrome with mosaicism. As a result, some cells have just one copy of the X chromosome (45, 21+X0), whereas others have two copies (46, 21+XX). Mosaic people experience less severe symptoms.⁸

In this case, the karyotype revealed a mosaic pattern of 45, X/46, XX (1 percent/99 percent) with normal estradiol levels, a mild increase in testosterone, and regular menstruation. Despite these findings, we remain concerned about the presence of a breast disorder evident at Tanner stage 1. Breast development occurs in early embryonic life and progresses to form lactiferous ducts and the mammary gland by the 8th month of fetal development. Thelarche, marking the onset of puberty, typically begins between ages 8 and 13. During childhood and puberty, the breast bud and mammary gland enlarge under the influence of steroid hormones-estrogen and progesterone. Estrogen stimulates the development of adipose tissue and lactiferous ducts, while progesterone induces alveolar budding and lobular growth.⁹

The regular menstruation shows the estrogen activity in this patient, however the breast development may indicate unsatisfactory estrogen activity. It may be caused by estrogen-receptor resistance. The action of estradiol affects breast development and involves estrogen receptor α . Both estrogen receptors α and β are encoded by *Esr1* and *Esr2*, respectively. Studies on *Esr1* knockout mice demonstrate hypoplastic uteri and multicystic ovaries without corpus luteum, while the ablation of *ESR2* leads to reproductive abnormalities.¹⁰

Several case reports have described the occurrence of Turner syndrome mosaicism,

which is characterized by a low percentage of chromosomal deletions and is an unusual characteristic of TS. A 40-year-old lady presented with an inguinal lump and was subsequently diagnosed with mosaic-shaped TS (45X/46XX). After 26 years of marriage, the lady has never had a period and has never been pregnant. Physical examination revealed a 5'1" (155 cm) height, acceptable breast development but tiny nipples, and no pubic or axillary hair. The inguinal mass has ovotestis sonomorphology and an atrophic uterus, as shown on ultrasound. Turner Mosaic Syndrome was verified by the karyotype, which showed 46XX (96%)/45X (4%).³

A case of Turner syndrome mosaicism was also described in a 58-month-old lady with small height. Except for his low height and cubitus valgus, he exhibits no TS dysmorphology. Turner syndrome mosaicism karyotype 45,X (18 cells)/47,XXX (7 cells) was discovered by cytogenetic analysis of 25 blood lymphocytes.¹¹

The most consistent phenotypic finding is short stature. However, current research suggests that individuals with mosaic TS have an increased likelihood of experiencing menstruation and achieving pregnancy. Gonadal dysgenesis stands as a defining characteristic of TS, with approximately 90% of patients requiring hormone replacement therapy (HRT) to initiate puberty. Nonetheless, a subset of children with TS does undergo spontaneous pubertal maturation and menarche, occurring in about 10% of cases in monosomy 45,X. Patients with TS mosaicism such as 45X/47XXX exhibit a higher propensity for spontaneous menstruation. Fertility is generally diminished in TS, albeit the degree varies based on the specific chromosomal mutation. Women with mosaicism for a normal cell lineage of 46, XX, a cell lineage of 47,XXX, or an extremely distal Xp deletion are more likely to experience spontaneous fertility.^{11,12}

The clinical presentation in this case is notably unique, particularly with the presence of mild hyperandrogenism. However, the authors have not conclusively determined the cause of hyperandrogenism. In Turner syndrome, manifestations of hyperandrogenism can occur in cases of mosaicism or upon detecting a Y chromosome through PCR and FISH array examinations. Notably, in this case, neither the presence of a Y chromosome nor virilization was identified. The primary concern regarding the presence of a Y chromosome lies in the elevated risk of developing gonadoblastoma or other

tumors. However, the role of the Y chromosome in oncogenesis remains controversial. In instances where there is suspicion, laparoscopy may be necessary to ascertain the presence of gonads. Nevertheless, in this particular case, there appears to be a tendency toward non-identification of gonads.^{13,14}

Therapy in this case

The treatment administered is mostly determined by the clinical presentation. In this case, hormonal tablets (drospirenone and ethynyl estradiol) were used to treat secondary sex development problem, and after two cycles of treatment, secondary sex development progressed from tanner 1 to tanner 2. The improvement after hormonal therapy was seen in parameter of breast development and axillary hair, growing from tanner 1 to tanner 2.

Hormonal treatment is required to induce and maintain secondary sex development in this scenario. The 2016 International Turner Syndrome Meeting in Cincinnati suggested that estrogen replacement medication be begun between the ages of 11 and 12, and gradually escalated to adult doses over the course of 2-3 years.¹⁵

Due to the lack of X chromosome, one with TS may be involved in the risk of developing skin neoplasms, colorectal cancer and CNS tumor.¹⁶ The risk of cancer are given with the administration of ethynyl estradiol. In the oral contraceptive therapy, ethynyl estradiol level range from 20 mcg to 50 mcg, which may increase the activity of Human Telomerase Reverse Transcriptase (hTERT). Inhibition of hTERT in immortal cells will lead to telomere shortening and apoptotic cells death, therefore hTERT activity indicate immortal and proliferation of cancer cells. Estrogen Receptor and Estrogen Response Element will cause the hTERT gene expression.¹⁷

To lower the risk of cancer, including endometrial cancer and/or breast cancer linked with extended estrogen exposure, progestins should be introduced when bleeding has occurred or after 2 years of estrogen therapy. To reduce bleeding, progesterone may be administered for 10 days each month, and adult women with TS should continue to take combination estrogen and progesterone.

The choice of progesterone type is according to the patient's clinical condition. Hyperandrogenism in this case is a consideration for the clinician to administer drospirenone.

The use of fourth-generation combined oral contraceptive with novel progestine drospirenone have natural progesterone effect, including anti-mineralocorticoid and anti-androgen activities.¹⁸ The other progesterone type that can be administered is nomegestrol acetate, which has a good tolerability profile and neutral metabolic characteristic. It is selective for receptor binding progesterone and have smaller activity against many steroid receptor, which gives no androgenic, estrogenic, glucocorticoid and mineralocorticoid effect.¹⁹

Fertility in this case

Fertility in TS individuals is normally poor, however it varies depending on the genetic abnormalities detected. Women with mosaicism for the 46,XX normal cell lineage, the 47,XXX cell lineage, or the most distal Xp deletion are more likely to have spontaneous fertility.¹⁰ Even if a woman with TS experiences spontaneous menarche and normal menstrual cycles, ovarian failure will ultimately develop, and the odds of miscarriage and life-threatening cardiovascular problems (aortic dissection and severe hypertension) remain substantial, even during pregnancy.⁹ Pregnancy in a woman with Turner syndrome, whether with an autologous oocyte or from a donor, is considered high risk since it might induce maternal and fetal difficulties. Any woman with TS who intends to become pregnant should be informed about the following informations;²⁰ Increased risk of miscarriage, Increased risk of fetal chromosomal abnormalities in pregnancies fertilized with autologous oocytes, High risk of maternal morbidity and mortality due to cardiovascular and metabolic complications, Obligation to transfer only one embryo in case of IVF-DO, to minimize the risk of multiple pregnancy, Increased risk of CS due to medical complications and narrow pelvic outlet in patients with Turner syndrome, The need for close follow-up by a multidisciplinary team, preferably in a tertiary care center, Risk of obstetric and neonatal complications (IUGR, prematurity, preeclampsia).

While research data is limited, it appears that women with Mosaic Turner Syndrome have a lower risk of cardiovascular and obstetric complications. Therefore, it is advisable for these women to undergo a comprehensive preconception checkup to assess their risks and for subsequent follow-up.²⁰

CONCLUSION

Mosaicism in Turner syndrome remains a possibility, and the severity of clinical symptoms corresponds to the extent of defective chromosomes. The variability of mosaicism in Turner syndrome necessitates therapy tailored to the presenting symptoms. This case highlights secondary sex development issues accompanied by mild hyperandrogenism. Despite the patient's regular menstruation indicating estrogen activity, the breast development remains at Tanner stage 1. Breast growth disorder may involve estrogen activity and sensitivity of estrogen receptors, and the administration of combination hormonal treatment can aid in enhancing secondary sex development.

ACKNOWLEDGEMENTS

The authors would like to thank Head of Moewardi Hospital, all staff in Sekar Infertility Clinic Dr. Moewardi Hospital and all staff in Pediatric Department for supporting the research and writing process.

CONFLICT of INTEREST

The authors have no conflicts of interest to disclose.

AVAILABILITY of DATA and MATERIALS

The data that support the findings of the present study are available in Medical Record Department of Dr. Moewardi Hospital, Surakarta.

Patient Consent for Publication

Patient provided consent for publication.

REFERENCES

- Altunyurt S, Acar B, Guclu S, et al. Mosaic form (45X/46XX) of Turner's syndrome: A case report. *J Reprod Med.* 2002;47(12):1053-4.
- Cui X, Cui Y, Shi L, et al. A basic understanding of Turner syndrome: Incidence, complications, diagnosis, and treatment. *Intractable & Rare Diseases Research.* 2018;7(4):223-8.
- Mathuriya G, Dave A. Rare Presentation of Mosaic Form (45X/46XX) of Turner's Syndrome. *J Obstet Gynecol Ind.* 2014;64:76-8.
- Shankar RK, Backeljauw PF. Current best practice in the management of Turner syndrome. *Ther Adv Endocrinol Metab.* 2018;9(1):33-40. doi: 10.1177/2042018817746291. Epub 2017 Dec 18. PMID: 29344338; PMCID: PMC5761955.
- Gravholt CH, Viuff MH, Brun S, et al. Turner syndrome: mechanisms and management. *Nat Rev Endocrinol.* 2019;15(10):601-14.
- Kesler SR. Turner Syndrome. *Child and adolescent psychiatric clinics of North America.* 2007;16(3):709.
- Milani DAQ, Chauhan PR. *Genetics, Mosaicism.* StatPearls Publishing. 2021. <https://www.ncbi.nlm.nih.gov/books/NBK559193/>
- Armstrong JM, Malhotra NR, Lau GA. Seminoma In A Young Phenotypic Female With Turner Syndrome 45,XO/46,XY Mosaicism: A Case Report with Review of the Literature. *Urol.* 2020;139:168-70.
- Mareti E, Vatopoulou A, Spyropoulou GA, et al. Breast Disorder in Adolescence: A Review of Literature. *Breast Care.* 2021;16(2):149-55.
- Quaynor SD, Stradtman, Jr EW, Kim HG, et al. Delayed Puberty and Estrogen Resistance in a Woman with Estrogen Receptor α Variant. *N Engl J Med.* 2013; 369(2): 164-71.
- Kim MJ, Jeong HR. Spontaneous Sexual Development and Heavy Menstrual Bleeding in 45,X Monosomy and 45,X/47, XXX Mosaic Turner Syndrome and a Review of the Literature. *J Pediatr Adolesc Gynecol.* 2020;33(5):602-6.
- Sybert VP. Phenotypic effects of mosaicism for a 47, XXX cell line in Turner syndrome. *J Med Genet.* 2002;39:217.
- Oliviera RMR, Verreschi ITN. Y Chromosome in Turner Syndrome : review of the literature. *Sao Paulo Med. J.* 2009;127(6):373-8.
- Diao Y, Zheng Q, Chen Z, et al. Hyperandrogenism in a girl with Turner Syndrome: A case report. *Med.* 2019;98:34.
- Yang S. Diagnostic and therapeutic considerations in Turner syndrome. *Annals Pediatr Endocrinol Metab.* 2017;22(4):226-30.
- Viuff MH, Stochholm K, Lin A, et al. Cancer occurrence in Turner Syndrome and the effect of sex hormone substitution therapy. *Eur J Endocrinol.* 2021; 184(1): 79-88
- Nurseta T, Wijasa A, Sitompul B. Impact of Ethynil Estradiol to Human Telomerase Reverse Transcriptase Activity on Complete Hydatidiform Mole Culture. *Indones J Obstet Gynecol* 2016; 4(2): 93-6.
- Li L, Zhang R, Zeng J, et al. Effectiveness and safety assessment of drospirenone/ethynyl estradiol tablet in treatment of PCOS patients: a single center, prospective, observational study. *BMC womans's Health.* 2020;20(39) : 1-7
- Tindar M, Effendi Y, Abadi A, Theodorus. A Comparative Study of Norgestrel Acetate and a Combination of Ethinylestradiol and Levonorgestrel for Delaying Menstruation among Umrah Pilgrims. *Indones J Obstet Gynecol.* 2018; 6(1): 45-9
- Bouet PE, Godbout A, El Hachem H, et al. Fertility and Pregnancy in Turner Syndrome. *J Obstet Gynecol Can.* 2016;38(8):712-8.