

## Case Report

## Successful Pregnancy after hCG/hMG Treatment in an Azoospermic Male with Idiopathic Hypogonadotropic Hypogonadism

### *Keberhasilan Kehamilan setelah Pengobatan hCG/hMG pada Pria Azoospermia dengan Hipogonadisme Hipogonadotropik Idiopatik*

Cheyon Park, Gyun-Ho Jeon

Department of Obstetrics and Gynecology  
University of Inje College of Medicine  
Haeundae Paik Hospital  
Busan, South Korea

#### Abstract

**Objective:** To report a rare case of idiopathic hypogonadotropic hypogonadism (IHH), one of the correctable causes of male infertility, with previous literature reviews.

**Methods:** A case report with previous literature reviews.

**Case:** A 29-year-old male was referred due to primary infertility with azoospermia. Laboratory investigations revealed low serum gonadotrophin levels and testosterone with normal appearance of pituitary gland magnetic resonance imaging. 9 months of human chorionic gonadotropin (hCG) treatment was followed by human menopausal gonadotropin (hMG) treatment under the suspected diagnosis of IHH. Spermatozoa were firstly detected after 10 months from the initial treatment and sperm concentration rose in  $14 \times 10^6/\text{ml}$  after 18 months treatment. After succeeding in twin pregnancy with IVF-ET procedure and fullterm live birth, his hCG/hMG treatment was changed into testosterone replacement therapy because they did not want an additional pregnancy with maintaining an approlakite male hormone level.

**Conclusion:** This case report shows that a thorough and careful examination of whether it is a reversible cause is necessary and important in the approach to male infertility. In addition, it further proves that, in the case of IHH, a continuous long-term gonadotrophic stimulation therapy contributes to successful pregnancy and may need a testosterone replacement therapy after childbirth.

**Keywords:** azoospermia, gonadotropin, human chorionic gonadotropin, hypogonadotropic hypogonadism, infertility.

#### Abstrak

**Tujuan:** Untuk melaporkan kasus langka hipogonadisme hipogonadotropik idiopatik (IHH), salah satu penyebab infertilitas laki-laki yang dapat diperbaiki, dengan tinjauan literatur sebelumnya.

**Metode:** Sebuah laporan kasus dengan tinjauan literatur sebelumnya.

**Kasus** Seorang laki-laki berusia 29 tahun dirujuk karena infertilitas primer dengan azoospermia. Pemeriksaan laboratorium menunjukkan kadar gonadotropin serum yang rendah dan testosteron dengan gambaran normal dari pencitraan resonansi magnetik kelenjar pituitari. 9 bulan pengobatan human chorionic gonadotropin (hCG) diikuti dengan pengobatan human chorionic gonadotropin (hMG) di bawah dugaan diagnosis IHH. Spermatozoa pertama kali terdeteksi setelah 10 bulan dari pengobatan awal dan konsentrasi sperma meningkat pada  $14 \times 10^6/\text{ml}$  setelah 18 bulan pengobatan. Setelah berhasil hamil kembar dengan prosedur IVF-ET dan kelahiran hidup cukup bulan, pengobatan hCG/hMG-nya diubah menjadi terapi penggantian testosteron karena mereka tidak menginginkan kehamilan tambahan dengan mempertahankan kadar hormon laki-laki yang sesuai.

**Kesimpulan:** Laporan kasus ini menunjukkan bahwa pemeriksaan menyeluruh dan hati-hati apakah penyebab reversibel diperlukan dan penting dalam pendekatan infertilitas laki-laki. Selain itu, lebih lanjut membuktikan bahwa, dalam kasus IHH, terapi stimulasi gonadotropik jangka panjang yang berkelanjutan berkontribusi pada keberhasilan kehamilan dan mungkin memerlukan terapi penggantian testosteron setelah melahirkan.

**Kata kunci:** azoospermia, gonadotropin, human chorionic gonadotropin, hipogonadotropik hipogonadisme, infertilitas.

**Correspondence author.** Gyun H. Jeon. Department of Obstetrics and Gynecology  
University of Inje College of Medicine. Haeundae Paik Hospital. Busan, South Korea  
Email: jeon285@hotmail.com

## INTRODUCTION

Idiopathic hypogonadotropic hypogonadism (IHH) is rare and its incidence is known as 1-10 cases per 100,000 births.<sup>1,2</sup> IHH is caused by deficient production, secretion or action of gonadotropin-releasing hormone (GnRH) and can be diagnosed through the presence of low testosterone and low gonadotropin levels without any structural or functional abnormalities in the hypothalamic-pituitary-gonadal axis.<sup>3</sup> Gonadotropin replacement is known as the treatment of choice to induce spermatogenesis in a male with hypogonadotropic hypogonadism.<sup>2</sup>

Most IHH patients go through the state of azoospermia if not treated with gonadotropin stimulation and testosterone therapy. Exogenous gonadotropin therapy can be a practical tool for desired clinical pregnancy of many infertile couples as it was demonstrated that the presence of case where progressively motile and normally formed sperm produced was observed in patients who received the therapy. Exogenous gonadotropin therapy includes follicle stimulating hormone (FSH)/ luteinizing hormone (LH) preparations that can be used for the treatment of idiopathic spermatogenic failure. Since human chorionic gonadotropin (hCG) has the biologic activity of LH but a longer half-life in the circulation; it stimulates the Leydig cells of the testes to synthesize and secrete testosterone, hCG is used to replace LH in men who have secondary hypogonadism and desire to become fertile. Testosterone plays a role in helping the Sertoli cells, which line the seminiferous tubule and contain androgen receptors, to produce spermatozoa.<sup>4</sup>

Hypogonadotropic hypogonadism (HH) leads to not only infertility but also to a significantly decreased quality of life and problems such as reduced muscle mass, energy, libido, facial and pubic hair, small genitalia, failure of voice to deepen, etc. Furthermore, the patients might also develop low self-esteem, depression and osteoporosis later in life because of low testosterone level in their bodies. Testosterone replacement can be applied to improve these problems in case who do not want the pregnancy.<sup>5</sup>

To the best of our knowledge, there are no established guidelines of therapeutic method for IHH yet, and no information on reversal rate of IHH after hormone replacement therapy although there were a few reports on hormonal restoration

of IHH.<sup>3,6</sup> Here, we present a rare case of IHH who had a successful experience of pregnancy after hCG/hMG treatment with previous literature reviews.

## CASE

A 29-year-old male was referred due to primary infertility, with no known comorbidity. He was married two years ago and had been started to try conception without contraception for 2 years. He had no previous medical and surgical history and did not have any familial genetic abnormality history. Also, he did not notice anything abnormal with his sexual function except that watery semen was found. He had no history of headache, deficiency in smell, visual problems, and trauma.

On physical examination, his blood pressure was normotensive and his height and weight were 174 cm and 82.2 kg. His Tanner scale of external genitalia and pubic hair were all 2. The testicular volume was small, about 5ml in size. He had shown no sign of gynecomastia and other abnormalities were not detected on physical examination.

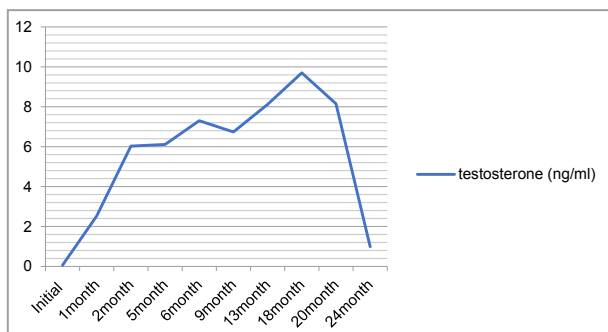
The initial laboratory finding showed low levels of LH, FSH and testosterone as 0.6 mIU/mL, 0.6 mIU/mL and 1.17 pg/mL, respectively. The levels of prolactin, thyroid stimulating hormone (TSH) and free thyroxine 4 (fT4) were normal (Table 1). The semen analysis test could not be performed due to the patient's failure in ejaculation. Chromosome analysis revealed a normal male karyotype (46, XY). The enhanced pituitary gland magnetic resonance imaging (MRI) scan revealed no abnormal growths or abnormalities in pituitary, hypothalamus and suprasellar areas.

**Table 1.** Initial Laboratory Investigation of the Patient

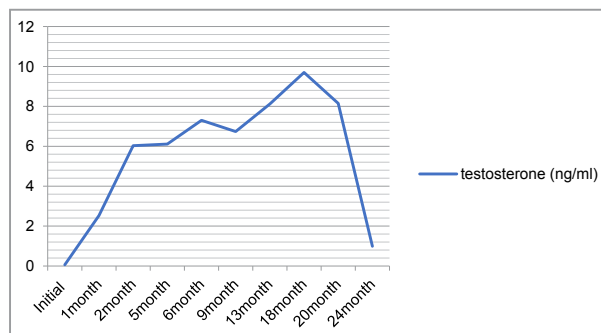
	<i>P-value</i>	<i>normal range</i>
LH(mIU/mL)	0.6	1.2-7.8
FSH(mIU/mL)	0.6	1.5-15.4
Free Testosterone(pg/mL)	1.17	8.90-42.50
Testosterone(ng/mL)	0.058	2.49-8.36
DHEAS(ug/dL)	117.6	160-449
Prolactin(ng/dL)	7.54	2.0-18
TSH(uIU/mL)	1.08	0.4-4.2
free T4(ng/dL)	1.11	0.89-1.76
ACTH(pg/mL)	73.0	7.2-63.3
Cortisol(ug/dL)	9.5	4.82-11.9

A gonadotrophin treatment was started with hCG (5,000 IU, IM) alone, three times a week for 9 months. Along with hCG treatment, serum testosterone level was measured monthly. For semen analysis, a computer-assisted semen analysis (CASA) was also executed monthly since the beginning of treatment. The patient's serum testosterone level increased to normal range along with his subjective sexual function and also his sexual contentment increased during the hCG treatment. Semen could be collected after one month of hCG treatment, however, azoospermia was sustained. Therefore, human menopausal gonadotropin (hMG) therapy, (75IU, SC, three times a week) was added after 9 months of initial hCG treatment, with reference to ASRM guidelines.<sup>7</sup>


Two months after the initiation of hCG hormonal therapy, patient's serum testosterone level increased to the normal range of 6.03 pg/mL (Figure. 1). Thus, we continued the hCG therapy with same dose of 5,000 IU. Although serum testosterone level was maintained in normal range for over 6 months, azoospermia was still sustained (Figure. 1~3a) and then hMG injection was added to the hCG therapy. From 2 months after additional hMG therapy, sperm was recognizable for the first time in the patient's semen (Figure. 3b), and 4 months later, more sperms with moderate motility were spotted (Figure. 3c). Semen analysis was performed serially at an interval of one or two months. As a result, we could observe an increasing in sperm count of 14.0 million/ml and its motility of 30.8% at 9 months after additional hMG therapy. (Figure. 2).



**Figure 1.** Change of Serum Testosterone Levels during hCG/hMG Treatment



**Figure 2.** Serial Results of Computer Assisted Semen Analysis



**Figure 3.** Gross findings of computer assisted semen analysis. (a) Initial analysis, (b) 11 months from initial treatment ( ; 2 months after hCG/hMG treatment), (c) 15 months from initial treatment ( ; 6 months after hCG/hMG treatment), (d) 1 month after discontinuation of hCG/hMG treatment, (e) 3 month after discontinuation of hCG/hMG treatment

Because his wife had bilateral tubal obstruction at the hysterosalpingography, they underwent an IVF-ET procedure after 9 months of the hCG/hMG therapy. And then they succeeded in twin pregnancy and full term delivery. Immediately after successful pregnancy, the husband wanted to discontinue gonadotrophin treatment for burden of self-injection and no further pregnancy plan. In follow-up tests three weeks after the discontinuation of hCG/hMG therapy, the serum free testosterone level decreased dramatically as 1.40 pg/mL. 3 months later from discontinuation of hCG/hMG therapy, semen analysis revealed decrease in sperm counts and azoospermia again (Figure. 3 d,e). Patient started testosterone replacement therapy with testosterone undecanoate 80mg, daily after 6 months from discontinuation of hMG/hCG therapy. From initiation of testosterone replacement, we had checked patient's testosterone level of serum at 6 months interval, which has been sustained in range of 1.24- 2.48 pg/mL

## DISCUSSION

In this case, we noted his deficiencies of secondary sexual development by the Tanner stages and low testosterone and low gonadotropin levels from the initial laboratory findings without any structural or functional abnormalities. There was no secondary factor – endocrine pathology, central neural pathology, etc - of hypogonadotropic hypogonadism found through multidimensional approaches in history taking and examination; hence, the diagnosis of IHH in this patient was confirmed.

The most common presentation of IHH is the complete absence of pubertal development with minimal testicular growth. The testes in such cases may be maldescended.<sup>8</sup> Testicular volume is usually < 4ml and hormone replacement treatment rarely results in complete normalization of sperm production. However, patients with hypogonadism of adult or post-pubertal onset are rare.<sup>9</sup> Although the case of our patient had also minimal pubertal development and testicular growth, his delayed referral at the age of 29 years can be regarded as unusual.

Multiple pathological factors have been known to cause HH. It includes genetic abnormality and any disease that affects the hypothalamic-pituitary axis. The relation between the failure of pulsatile gonadotropin releasing hormone (GnRH) secretion and gene mutation has been revealed in a few studies. However, genetic testing in IHH is challenging, given the genetic and allelic heterogeneity, as well as complex oligogenic inheritance patterns.<sup>10</sup> It is because we only tested karyotyping on the patient for genetic analysis and it was unclear to identify if the patient with IHH had a genetic impact.

Hormonal therapy for spermatogenesis can be applied with either gonadotrophins or pulsatile GnRH.<sup>11</sup> Exogenous pulsatile GnRH stimulates the FSH and LH secretion from the pituitary gland.<sup>12,13</sup> However, because of complex and time-consuming pulsatile therapies, today, only a few patients with hypogonadotropic hypogonadism are treated with pulsatile GnRH. In addition, pulsatile GnRH therapy seems to have no proven advantage over FSH plus hCG therapy in patients with hypothalamic HH. The lack of sufficient well-designed and randomized prospective studies did not allow firm conclusions on the best therapy for infertility in these patients.<sup>14</sup>

The exogenous substitution of testosterone is to maintain all androgen-dependent functions.

This therapy has been well established over decades, relatively convenient for male patients and comparably inexpensive.<sup>15</sup> In the case where patients desire offspring, the testosterone substitution therapy is no longer sufficient and has to be interrupted. The patients should then be treated with FSH preparations, in addition, with pharmacological preparation such as LH to stimulate intratesticular testosterone production by the Leydig cells. As the LH preparation hasn't been yet approved for male HH, patients are usually treated with hCG preparations with not identical but similar bioactivity. LH, by the use of its substitute hormone hCG, is always replaced before FSH. Because stimulation of hCG alone may be sufficient for spermatogenesis and hCG is considerably less expensive than exogenous FSH preparations.<sup>16,17</sup> In our case, 9 months initial hCG therapy was not enough to spermatogenesis thus we added FSH preparation using hMG which is less expensive than recombinant FSH and had also proved as an effective alternative treatment.<sup>18</sup> In our case, we also got successful result of spermatogenesis with hCG/hMG therapy.

In some cases, reported that 15 patients had sustained reversal of HH even after the discontinuation of the therapy.<sup>3</sup> Five of them received testosterone treatment alone, three were treated with only pulsatile GnRH therapy and the rest received a mixed regimen, including testosterone, gonadotropins or GnRH. Although the mechanism of reversal is unclear, it is inferred that the GnRH therapy somehow modified the hypothalamic neurons responsible for producing GnRH. This might lead to reversal of HH and initiation of spermatogenesis. A case of HPG axis recovery after testosterone therapy.<sup>6</sup> Although our patient had succeeded in spermatogenesis and pregnancy, his HPG axis was not recovered after gonadotrophin or testosterone treatment. Gonadotrophin therapy was followed by testosterone substitution therapy to maintain the androgen-dependent functions including sexual ability of erection and ejaculation.

## CONCLUSION

This study is a good example that shows the importance of differentiating reversible cause of infertility from irreversible cause by a thorough and careful examination. In addition, it further proves that, in the case of IHH, a continuous long-term gonadotrophic stimulation therapy (hMG/hCG) contributes to successful pregnancy and

childbirth. Further reports and related research will be needed for the cases with IHH reversal and established guidelines for therapeutic method of IHH.

### Conflicts of Interest Statement and Funding/Support Statement/Ethical clearance

The author(s) have no conflicts of interest and no funding/support relevant to this article. The Institutional Review Board of Inje University Haeundae Paik Hospital approved this study (No. 2021-03-007).

### REFERENCES

- Boehm, U., Bouloux, P., Dattani, M. et al. European Consensus Statement on congenital hypogonadotropic hypogonadism-pathogenesis, diagnosis and treatment. *Nat Rev Endocrinol.* 2015; 11:547-64
- Bianco, S., Kaiser, U. The genetic and molecular basis of idiopathic hypogonadotropic hypogonadism. *Nat Rev Endocrinol.* 2009;5:569-76.
- Raivio T, Falardeau J, Dwyer A, et al. Reversal of idiopathic hypogonadotropic hypogonadism. *N Engl J Med.* 2007;357:863-73.
- Finkel DM, Phillips JL, Snyder PJ. Stimulation of spermatogenesis by gonadotropins in men with hypogonadotropic hypogonadism. *N Engl J Med.* 1985;313(11):651.
- Bassil N, Alkaade S, Morley J. The benefits and risks of testosterone replacement therapy: a review. *Ther Clin Risk Manag.* 2009;5:427-48
- Rashid O, Ram N, Farooq S, et al. Idiopathic hypogonadotropic hypogonadism reversal after testosterone replacement in a 34-year-old male. *BMJ Case Rep.* 2017: bcr2016218729.
- Practice committee of the American society for Reproductive Medicine. Evidence-based treatments for couples with unexplained infertility: a guideline. *Fertil Steril.* 2020;13(2):305-22.
- Finkel DM, Phillips JL, Snyder PJ. Stimulation of spermatogenesis by gonadotropins in men with hypogonadotropic hypogonadism. *N Engl J Med.* 1985;313(11):651.
- Matsumoto, A.M. Hormonal therapy of male hypogonadism. *Endocrinol. Metabol Clin. N. Am.* 1994;23:857-75.
- Whitcomb, R.W. and Croweley, W.F. Diagnosis and treatment of isolated gonadotropin-releasing hormone deficiency in men. *J. Clin. Endocrinol. Metabol.* 1990;70:3-7.
- Sumko D, Weise SE, Wong L. Congenital idiopathic hypogonadotropic hypogonadism: a case report. *J Clin Case Reports.* 2014;4:371.
- Schopfl, J., Mehlretter, G., von Zumbusch, R. et al. Comparison of gonadotropin-releasing hormone and gonadotropin therapy in male patients with idiopathic hypothalamic hypogonadism. *Fertil. Steril.* 1991;56:1143-6.
- Behre HM, Nieschlag E, Partsch C-J, Wieacker P, Simoni M. Diseases of the hypothalamus and the pituitary gland. *Andrology. Male Reproductive Health and Dysfunction.* 3rd ed. Berlin: Springer 2010:169-92.
- Young J, Xu C, Papadakis GE, et al. Clinical management of congenital hypogonadotropic hypogonadism. *Endocrinol Rev.* 2019;40:669-710.
- Mao JF, Liu Zx, Nie M, et al., Pulsatile gonadotropin-releasing hormone therapy is associated with earlier spermatogenesis compared to combined gonadotropin therapy in patients with congenital hypogonadotropic hypogonadism. *Asian J Androl.* 2017;19:680-5.
- Behre HM, Clinical Use of FSH in Male Infertility, *Front. Endocrinol.* 2019;10:322.
- Casarini L, Lispi M, Longobardi S, et al., LH and hCG action on the same receptor results in quantitatively and qualitatively different intracellular signalling. *PLoS ONE.* 2012;7:e466682.
- Bucher D, Behre HM, Kliesh S, Nieschlag E. Pulsatile GnRH or human chorionic gonadotropin/human menopausal gonadotropin as effective treatment for men with hypogonadotropic hypogonadism: a review of 42 cases. *Eur J Endocrinol.* 1998;139:298-303.