

**Case Report**

## A large Parasitic Dermoid Cyst in the Pouch of Douglas: a Torsion Complication?

### *Kista demoid pada Pouch of Douglas: Apakah sebuah komplikasi torsio?*

Luay I. A. Atileh<sup>1</sup>, Nouf M. Khalifeh<sup>2</sup>

<sup>1</sup> Department of Obstetrics and Gynecology,  
Albasheer Hospital, Jordan Ministry of Health, Amman, Jordan.

<sup>2</sup> Arizona State University, Arizona, United States of America

#### Abstract

**Objective:** To identify the underlying etiology of dermoid cysts in the pouch of Douglas.

**Methods:** Case report.

**Case:** A 44-year-old woman presented to our clinic complaining of chronic, dull-aching lower abdominal pain of one-month duration. Pelvic ultrasound examination showed an eight-centimeter cystic appearing lesion in the right adnexa. Computed tomography (CT) suggested the diagnosis of dermoid cyst. Laparoscopy revealed a residual ovarian tissue on the right side and an eight-centimeter cystic mass occupying the pouch of Douglas. The entire specimen was removed en bloc through the umbilicus incision inside a bag with no spillage. Histopathologic examination confirmed the diagnosis of a mature cystic teratoma.

**Conclusions:** Parasitic dermoid cysts are extremely rare entity especially those located in the pouch of Douglas. Autoamputation and reimplantation is the most accepted etiology to explain this phenomenon.

**Keywords:** autoamputation, dermoid cyst, douglas, laparoscopy, mature cystic teratoma.

#### Abstrak

**Tujuan:** Untuk mengidentifikasi etiologi yang mendasari kista dermoid di kantong Douglas.

**Metode:** Laporan kasus

**Kasus :** Seorang perempuan 44 tahun datang ke klinik kami dengan keluhan nyeri perut bagian bawah yang kronis dan nyeri tumpul selama satu bulan. Pemeriksaan USG panggul menunjukkan lesi kistik delapan sentimeter yang muncul di adneksa kanan. Computed tomography (CT) menyarankan diagnosis kista dermoid. Laparoscopi mengungkapkan jaringan ovarium sisa di sisi kanan dan massa kistik delapan sentimeter menempati kantong Douglas. Seluruh spesimen dikeluarkan secara en bloc melalui sayatan umbilikus di dalam kantong tanpa tumpahan. Pemeriksaan histopatologi mengkonfirmasi diagnosis teratoma kistik matur.

**Kesimpulan:** Kista dermoid parasit adalah entitas yang sangat langka terutama yang terletak di kantong Douglas. Autoamputasi dan reimplantasi adalah etiologi yang paling diterima untuk menjelaskan fenomena ini.

**Kata kunci:** autoamputasi, douglas, kista dermoid, laparoscopi, teratoma kistik matur.

**Correspondence author. :** Luay Abu Atileh . Department of Obstetrics and Gynecology,  
Albasheer Hospital, Jordan Ministry of Health, Amman, Jordan. luayatileh@gmail.com

Received: December, 2020 Accepted: June, 2021

Published: July, 2021

#### INTRODUCTION

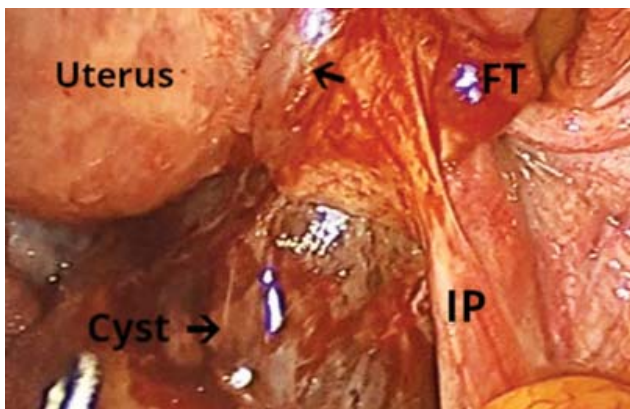
Mature cystic teratomas also known as dermoid cysts are considered one of the most common ovarian germ cell neoplasms, with a reported incidence between 5% and 25% of all ovarian tumors.<sup>1</sup> However, parasitic dermoid cyst is considered a very rare entity with a cumulative incidence of 0.4% of all ovarian mature cystic teratomas.<sup>2</sup> The most common secondary site of implantation of parasitic dermoid cysts is reported to be the omentum due to its unique role as an intra-abdominal anti-inflammatory barrier.<sup>3</sup> Up to our knowledge only 20 cases of

parasitic dermoid cysts have been reported to be found in the pouch of Douglas.<sup>4-8</sup> In this report we are presenting a rare case of parasitic mature cystic teratoma found in the pouch of Douglas in a 44-year-old woman, that was managed laparoscopically along with a literature review.

#### CASE

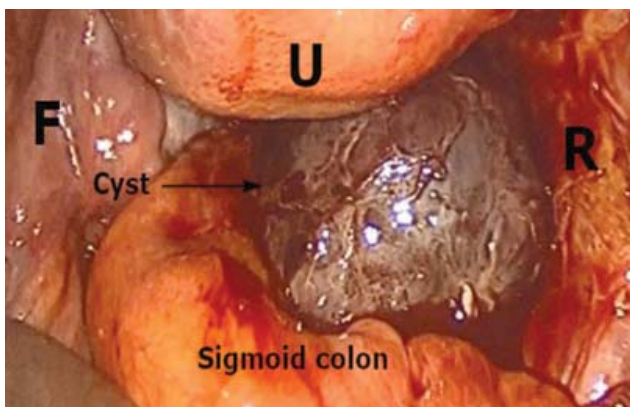
A 44-year-old woman, presented to our clinic complaining of chronic, dull-aching lower abdominal pain of one-month duration. she had no relevant medical or surgical history. Abdominal and pelvic examination were

unremarkable. Pelvic ultrasound examination showed eight-centimeter cystic lesion in the right adnexa. Computed tomography (CT) showed an eight cm right adnexal well defined oval shaped fat density thin walled multiseptated cystic lesion containing tubular structure, tufts of hair, calcific focus confirming the diagnosis of a dermoid cyst suggested to be originating from the right ovary. laboratory tests including the level of CA125 were all within normal range. Laparoscopy was performed and intraoperative findings Revealed a normal uterus, a 4 cm left para ovarian cyst, a residual tissue on the right side, which was connected to the right utero ovarian ligament and identified to be a remnant of the right ovary. It was slightly adherent along with the fallopian tube on the same side to an eight-centimeter, round, dark blue cystic mass occupying the pouch of Douglas (Figure.1).



**Figure 1.** Laparoscopic view showing the cyst of around 8 cm occupying the pouch of Douglas. IP: indicates the infundibulopelvic ligament. FT: indicates the fimbria of the fallopian tube. Black arrow: indicates the residual ovarian tissue.

The mass was also adherent to the posterior uterine wall, the distal part of the sigmoid colon, and the rectum (Figure 2).



**Figure 2.** Laparoscopic view of the parasitic dermoid cyst showing it as an isolated mass, separate from the left adnexa and fallopian tube (F), adherent to the sigmoid colon, rectum (R), and the posterior uterine wall (U).

After adhesiolysis, the cystic mass was found to be completely isolated from both adnexa. There was no identifiable blood supply or a pedicle. The entire specimen was removed en bloc through the umbilicus incision without spillage using in-bag manual morcellation. The left para ovarian cyst was easily enucleated. The post-operative course was uneventful. The histopathological examination showed ovarian tissue surrounding a cystic lesion with widespread hemorrhagic necrosis with hair follicles and no evidence of malignant or immature components confirming the diagnosis of a strangulated dermoid cyst of the right ovary. The left para ovarian cyst was a benign mucinous cystadenoma.

## DISCUSSION

Teratomas are tumors arising from pluripotent stem cells that have the capacity to differentiate into any of the three germ cell layers giving rise to many tissues such as hair, bone, muscle, and others.<sup>9</sup> Mature cystic teratomas almost exclusively contain adult or fetal tissues or both. In very rare exceptions embryonic structures may also be present. Therefore the most classical site of mature cystic teratomas is the ovaries.<sup>10</sup> Nevertheless, extragonadal teratomas have been reported to occur in various sites with a predominant arrangement toward the median and paramedian positions.<sup>8,11</sup> The exact etiology behind the development of extragonadal teratomas is poorly understood, however several theories have been proposed to explain this phenomenon. The first theory suggested the development of extragonadal teratoma from displaced primordial germ cells that might divert from their normal migratory path from the yolk sac toward the developing genital ridge.<sup>9,11</sup> Yet this theory is not applicable to our case due to the presence of ovarian tissue within the teratoma. The second theory puts forward the supernumerary or ectopic ovary as the origin of extragonadal teratoma which might be congenital or acquired after pelvic inflammatory disease or previous surgery.<sup>7,11</sup> The patient in our case had no previous surgical history and no renal anomalies were observed to explain any congenital abnormality related to the adnexa. The third and final theory is the most popular theory to explicit the presence of extragonadal teratomas in the abdominal cavity which assumes that the extragonadal teratoma is autoamputated

from an ovarian site and subsequently implanted in another extragonadal site.<sup>11</sup>

Theoretically autoamputation is considered a consequence of a previous torsion which is reported to be the most common complication an ovarian cystic tumor may endure.<sup>1</sup> The impairment of the blood supply will lead to venous and lymphatic congestion which will induce necrosis and atrophy in acute settings. On the other hand, if the torsion is subacute or chronic this will lead to the formation of collateral blood supply with the surrounding organs. In very rare cases the torsion may prompt the formation of parasitic cyst that is completely detached from its pedicle.<sup>7,11</sup> To determine the etiology clinically we depend on the state of the fallopian tube and the histopathology report that support the presence

of ovarian stromal tissue, since the actual moment of autoamputation is not inspected.<sup>7</sup> Whereas the most common site of parasitic dermoid cyst implantation is reported to be the omentum, the pouch of Douglas is considered to be a very rare site of implantation that needs to be further investigated.<sup>8</sup> Based on this, we performed a PubMed search using the following key words: "parasitic" or "extragonadal," "dermoid" or "teratoma," "cul-de-sac" or "Douglas" which brought forth 20 articles that we summarized in Table 1.<sup>4-8</sup> The patients age ranged from 18 to 83 years, with predominance toward childbearing and premenopausal age. Eleven patients out of 20 suffered from abdominal pain as a primary symptom. On the contrary, 5 patients were completely asymptomatic (Table 1).

**Table 1:** Summary of Mature Cystic Teratomas Found in the Pouch of Douglas

Author, Ref. number	year	age	symptom	Size (cm)	State of the ovaries	State of the fallopian tubes	histopathology	approach	etiology
Lefkowitz JH, <sup>7</sup>	1978	40	Urinary retention	11.5×9.5×7.5	Grossly normal	Not mentioned	MCT <sup>a</sup> , no ovarian tissue	Laparotomy	Not specified
Turhan NO, <sup>7</sup>	2000	30	Yellow-green vaginal discharge	4.69×4.36×2.99	Both normal	Both normal	MCT, no ovarian tissue	Laparoscopy	Not specified
Chen HJ, <sup>7</sup>	2004	61	Lower abdominal pain	4.5×4	Rt. Ovarian cyst and atrophic Lt. ovary	Both normal	MCT, no ovarian tissue	Laparoscopy	Not specified
Kobayashi Y, <sup>7</sup>	2006	61	Asymptomatic	unknown	Both normal	Not mentioned	MCT, no ovarian tissue	laparotomy	Not specified
Kusaka M, <sup>7</sup>	2007	24	Sharp left lower quadrant pain	2×3.5×4	Lt. ovary not identified, uterus and Rt. Adnexa were normal	Left tube not identified	MCT, viable normal ovarian tissue detected	Laparoscopy	Auto-amputation
Khoo CK, <sup>7</sup>	2008	29	Bilateral lower abdominal pain	7.2×7.1×4.3	Rt. Ovarian dermoid cyst, normal Lt. ovary	Both normal	MCT, no ovarian tissue	Laparoscopy	Auto-amputation
Peitsidou A, <sup>7</sup>	2009	33	Admitted to the labor ward for cesarean section	8×5	Absent Rt. Ovary, normal Lt. ovary	Rt. Tube was blind ended, Lt. tube was normal	MCT, normal ovarian tissue detected	Laparotomy	Auto-amputation
Sinah R, <sup>7</sup>	2009	23	Abdominal pain	Largest is 4×3 in the pouch of Douglas	Normal Lt. ovary, underwent Rt. Oophorectomy	Not mentioned	MCT, no ovarian tissue	Laparoscopy	Recurrence after previous cystectomy
Bartlett CE, <sup>7</sup>	2009	29	Abdominal pain	6×8	small Rt ovary, normal left ovary	Dilated Rt. tube, normal Lt. tube	MCT, no ovarian tissue	laparoscopy	Auto-amputation
Bambao C, <sup>7</sup>	2010	50	asymptomatic	Not mentioned	Both atrophic	Not mentioned	MCT, no ovarian tissue	laparoscopy	Not specified
Matsushita H, <sup>7</sup>	2011	69	Lower abdominal pain	7	Atrophic Rt. ovary	Not mentioned	No ovarian tissue	laparotomy	Auto-amputation
Takeda A, <sup>7</sup>	2012	26	Positive urine pregnancy test, suspected ectopic pregnancy	2.9	Left ovarian dermoid cyst, normal right ovary	Both normal	Not mentioned	laparoscopy	Auto-amputation
Tokunaga M, <sup>7</sup>	2012	37	asymptomatic	6	Left adnexa removed due to previous immature teratoma, Rt. ovarian cyst	Rt. Tube normal	MCT, no ovarian tissue	laparoscopy	Not specified
Eda M, <sup>7</sup>	2012	83	Postmortem	8.1×7.4×6.1	Rt ovary intact, Lt ovary absent	Rt tube intact, Lt tube tapered.	MCT, no ovarian tissue	Anatomical dissection	Auto-amputation
Greene A, <sup>12</sup>	2014	48	Right sided flank pain	7.3×5	Rt ovary not found in normal anatomical position, Lt ovary normal	Rt. Hydrosalpinx, Lt. tube normal	MCT with viable ovarian tissue	laparoscopy	Auto-amputation
Kakuda M, <sup>7</sup>	2015	41	Abdominal pain	4	Small, defected Lt. ovary, normal Rt. ovary	Lt. tube was blind ended, normal Rt. Tube	MCT with ovarian stroma	laparoscopy	Auto-amputation
Ohshima K, <sup>6</sup>	2015	20	Lower abdominal pain	7×6.5×2.5	Both ovaries normal	Not mentioned	MCT, no ovarian tissue	laparoscopy	Displaced primordial germ cells
Jain P, <sup>8</sup>	2017	18	Abdominal pain	7×7	Both ovaries normal	Both tubes normal	MCT, no ovarian tissue	Laparoscopy converted to laparotomy	Not specified
John B, <sup>4</sup>	2017	32	asymptomatic	6	Lt. ovary not seen; Rt. Ovary normal	Distal portion of the Lt. tube was absent, normal Rt. Tube.	MCT, with ovarian tissue	laparoscopy	Auto-amputation
Sethi P, <sup>5</sup>	2019	40	Lower abdominal pain	15×15×10	Both ovaries normal	Not mentioned	MCT not arising from the ovaries	laparotomy	Displaced primordial germ cells

<sup>a</sup> Mature cystic teratoma

The state of the fallopian tubes and the histopathology report are both considered the pedestal of understanding and determining the underlying etiology. seven cases<sup>4,7,12</sup> manifested either fallopian tube abnormality or reported the presence of ovarian tissue microscopically, which strongly supports the theory of auto amputation among other proposed etiologies. We believe that the present case also demonstrates the autoamputation of a right ovarian teratoma depending on the macroscopic observation of the right ovary residuals and the presence of an isolated teratoma in the pouch of Douglas. Furthermore, the histopathology report confirmed the diagnosis of mature cystic teratoma and the presence of ovarian tissue which strongly supports the aforementioned theory. Regarding the approach, 13 cases were managed laparoscopically which is the recommended approach over laparotomy in such cases especially in premenopausal women.<sup>11</sup> The advantages of laparoscopy over laparotomy in managing benign adnexal tumors include better cosmetic results, less blood loss, less post-operative pain, decrease the need for analgesia, faster recovery, and shorter hospital stay. Therefore, the decision was made to perform laparoscopic removal of the cyst instead of laparotomy in our patient.

### CONCLUSION

In Conclusion, parasitic dermoid cysts are extremely rare entity especially those located in the pouch of Douglas. Autoamputation and reimplantation is the most accepted etiology to explain this phenomenon. Concerning the management, laparoscopy is by far the gold standard approach for treating such cases.

### REFERENCES

1. peterson WF, Prevost EC, Edmunds FT, Hundley JM, Morris FK. Benign cystic teratomas of the ovary; a clinico-statistical study of 1,007 cases with a review of the literature. *Am J Obstet Gynecol.* 1955;70(2):368-82. doi:10.1016/s0002-9378(16)37681-5.
2. Kim HG, Song YJ, Na YJ, Yang J, Choi OH. A rare case of an autoamputated ovary with mature cystic teratoma. *J Menopausal Med.* 2017;23(1):74. doi:10.6118/jmm.2017.23.1.74.
3. Ushakov FB, Meirou D, Prus D, Libson E, Benshushan A, Rojansky N. Parasitic ovarian dermoid tumor of the omentum - a review of the literature and report of two new cases. *Eur J Obstet Gynecol Reprod Biol.* 1998;81(1):77-82. doi:10.1016/s0301-2115(98)00144-4.
4. John B. Ectopic ovary with dermoid cyst as a result of possible asymptomatic autoamputation. *J Hum Reprod Sci.* 2017. doi:10.4103/jhrs.jhrs\_67\_17.
5. Sethi P, Purkait S. Mature cystic teratoma of douglas' pouch: a rare entity. *cureus.* 2019. doi:10.7759/cureus.5515.
6. Ohshima K, Umeda A, Hosoi A, Yamamoto T, Munakata S. Mature cystic teratoma in douglas' pouch. *case rep pathol.* 2015;2015(figure 2):1-4. doi:10.1155/2015/202853.
7. Kakuda M, Matsuzaki S, Kobayashi E, Yoshino K, Morii E, Kimura T. A case of extragonadal teratoma in the pouch of douglas and literature review. *J Minim Invasive Gynecol.* 2015;22(7):1311-7. doi:10.1016/j.jmig.2015.07.008.
8. Pooja G.J, Alka Shukla, Poonam Raikwar. Parasitic dermoid cyst. *Int J Med Heal Res.* 2017;3(9):90-2.
9. Sadler T, Langman J. *Langman's medical embryology.* 10th ed.; 2006.
10. Roth Lm, Talerma A. Recent advances in the pathology and classification of ovarian germ cell tumors. *Int J Gynecol Pathol.* 2006;25(4):305-320. doi:10.1097/01.pgp.0000225844.59621.9d.
11. Lee KH, Song Mj, Jung IC, Lee YS, Park EK. Autoamputation of an ovarian mature cystic teratoma: a case report and a review of the literature. *World J Surg Oncol.* 2016;14(1):1-7. doi:10.1186/s12957-016-0981-7.
12. Greene AD, Breborowicz AK, Hardart A. Torsion, autoamputation, and reimplantation of viable ovarian dermoid cyst. *crsls mis case reports from sls.* 2014;18(4):2-4. doi:10.4293/crsls.2014.00192.