

## Case Report

## Diagnosis and Management of Severe Peripartum Cardiomyopathy

### *Diagnosis dan Manajemen Kardiomiopati Peripartum Berat*

Sidhi Laksono<sup>1,2</sup>, Ananta S. Prawara<sup>3</sup>, Reynaldo Halomoan<sup>4</sup>

*1Department of Cardiology and Vascular Medicine, RS Pusat Pertamina, South Jakarta*

*2Faculty of Medicine, Universitas Muhammadiyah Prof. Dr. Hamka, Tangerang*

*3Faculty of Medicine, Universitas Diponegoro, Semarang*

*4Faculty of Medicine, Universitas Katolik Indonesia Atma Jaya, Jakarta*

#### Abstract

**Objective:** To describe the diagnosis and management of severe peripartum cardiomyopathy.

**Methods:** A case report.

**Case:** A 35-year-old woman presented with dyspnea and leg edema. The patient gave birth 3 months ago. The hemodynamic was unstable and the physical examination showed a mild rhonchi in the basal of the lung and pansystolic murmur in the apex. Echocardiography showed a dilated heart chamber and reduced ejection fraction (30%). The patient was diagnosed as severe PPCM. The initial management was to stabilize the patient using furosemide, catecholamine, and vasopressor administration. After the patient's condition was stable, ramipril, bisoprolol, and bromocriptine were given as heart failure therapy.

**Conclusions:** Patient with suspicion of PPCM should be managed thoroughly from detailed history taking to proper diagnostic testing such as echocardiography. Prompt treatment of severe PPCM according to the guideline will improve the cardiac function.

**Keywords:** catecholamines, echocardiography, peripartum cardiomyopathy, pregnancy, vasopressor.

#### Abstrak

**Tujuan:** Untuk mendeskripsikan mengenai diagnosis dan manajemen pasien pada kasus kardiomiopati peripartum yang berat.

**Metode:** Laporan kasus.

**Kasus:** Seorang Perempuan 35 tahun datang dengan dispnea dan edema tungkai. Pasien melahirkan 3 bulan lalu. Hemodinamik tidak stabil dan pemeriksaan fisik menunjukkan ronki ringan di basal paru dan murmur pansistolik di apeks. Ekokardiografi menunjukkan dilatasi ruang jantung dan fraksi ejeksi berkurang (30%). Pasien didiagnosis dengan PPCM berat. Penatalaksanaan awal adalah menstabilkan pasien dengan pemberian furosemid, katekolamin, dan vasopresor. Setelah kondisi pasien stabil, diberikan ramipril, bisoprolol, dan bromokriptin sebagai terapi gagal jantung.

**Kesimpulan:** Pasien dengan kecurigaan PPCM harus dikelola secara menyeluruh mulai dari anamnesa yang rinci hingga uji diagnostik yang tepat seperti ekokardiografi. Pengobatan segera untuk PPCM derajat berat yang sesuai dengan pedoman akan meningkatkan fungsi jantung.

**Kata kunci:** ekokardiografi, kardiomiopati peripartum, katekolamin, kehamilan, vasopresor.

**Correspondence author.** Sidhi Laksono. sidhilaksono@uhamka.ac.id

Received: October 28, 2020

Accepted:

Published:

## INTRODUCTION

Peripartum cardiomyopathy (PPCM) is a rare condition that could be life-threatening. It is characterized by a disruption in systolic phase and the presence of sign and symptoms of heart failure at the end of pregnancy and first 5 months after the delivery process, with left ventricular ejection fraction (LVEF) <45%.<sup>1</sup> PPCM is different from other heart failure. Diagnosis of PPCM is made after excluding any other possible causes

of heart failure (pregnancy-related myocardial infarction and pre-existing heart disease).<sup>2</sup>

The incidence of PPCM differs in numerous countries. In USA, the overall incidence from 2004 to 2011 was about 1 in 968 live births.<sup>3</sup> Nigeria and Haiti reported a higher incidence; 1 in 100 pregnancies and 1 in 300 pregnancies respectively.<sup>4</sup> The study about PPCM incidence in Asia is lacking. However, a study showed that the incidence of PPCM was about 1 in 3.790 live births.<sup>5</sup> Heart dysfunction in PPCM may cause

complications that range from mild (shortness of breath and swelling of the leg) to severe (cardiogenic shock and death). The mortality rates of PPCM was reported to be as high as 30% worldwide.<sup>4</sup> Risk factors for PPCM may vary from hypertensive disorders, older age during pregnancy, and also African population.<sup>1</sup>

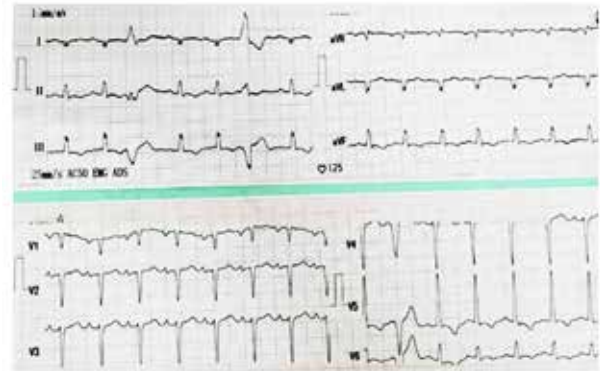Although the definition and diagnostic criteria of PPCM is already available, PPCM may present a challenge for physician in clinical settings because of the nonspecific signs and symptoms that could be similar to the physiologic changes in pregnancy. Therefore, it is important to evaluate pregnant/post-partum woman with heart failure symptoms.<sup>4</sup> The purpose of this case report is to share the knowledge about how to diagnose and treat patients with severe PPCM based on our experience in managing 35-years-old woman with PPCM.

### CASE

A 35-year-old woman came to the emergency room, with shortness of breath and leg edema in the last 3 months after given birth to her first baby. She reported that the shortness of breath was exacerbated by activity. She did not check herself to the doctor earlier because she thought that this was normal in pregnancy. There was no similar symptom and no history of hypertension during the pregnancy. The patient looked ill with GCS E4V5M6. The initial examination for vital signs were notable with blood pressure of 86/50 mmHg, heart rate of 110 beats/minute, respirations of 28x/minute, and oxygen saturation of 95% on room air. The patient did not have fever.

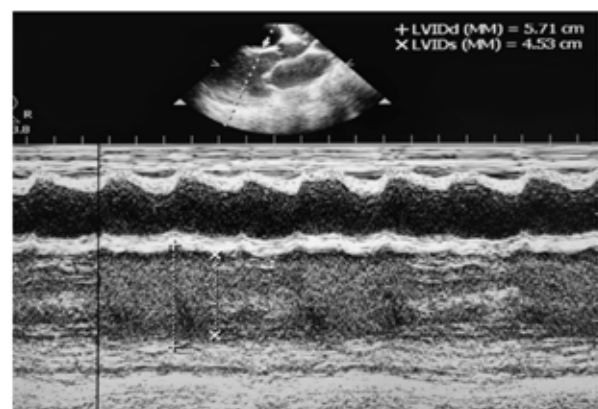
As an initial management, we gave oxygen to the patient 3 liter/minute with nasal canule. Through the physical examination, we found a grade 4 pansystolic murmur at the apex. We also found mild rhonchi at the basal of the lung. We conducted an electrocardiography on the patient. The result showed a sinus tachycardia with heart rate of 125 beats/minute with right axis deviation. There was also an inverted T wave at III, V5, V6, and aVF. The ECG also showed a right atrial dysfunction, left atrial enlargement, and incomplete left bundle branch block (LBBB). Ventricular extrasystole was also found at lead I and III (figure 1). Blood test was done and the result showed a shift-to-the right leukocyte count. The electrolyte evaluation showed a mild hyponatremia (131 mmol/L), hyperchloride (109

mmol/L), and hypocalcemia. The urinalysis was negative for proteins.



**Figure 1.** ECG of the patient showed T-wave inversion at III, V5, V6, and aVF right atrial dysfunction, left atrial enlargement, and incomplete left bundle branch block (LBBB), and ventricular extrasystole at I and III

We decided to perform echocardiography to evaluate the heart of the patient. The left ventricular internal diameter end diastole (LVIDd) was 5.71cm and the left ventricular internal diameter end systole (LVIDs) was 4.53cm, suggestive of an increased diameter of the left ventricle (figure 2). The mitral valve showed a moderate to severe regurgitation and the tricuspid was mild to moderate regurgitation, supported by Doppler examination. The patient had a reduced LVEF (30%). Echocardiography prior to pregnancy, the LVEF was normal (61%) with mild mitral regurgitation due to mitral valve prolapse. From the result of thorough examination, the diagnosis of severe peripartum cardiomyopathy was made.



**Figure 2.** Echocardiography showed a dilated left ventricle.

After diagnosing the patient with severe PPCM because of the hemodynamic instability, we initiated the treatment with furosemide IV drip, followed by the administration of dobutamine. We also corrected the hypocalcemia

with calcium gluconate IV. However, no improvement can be seen in the patient, so that we added norepinephrine. The administration of norepinephrine improved the hemodynamic of the patient. The patient was monitored closely and her condition kept on improving until declared stable. The patient was prescribed with oral bromocriptine, ramipril, and bisoprolol. She was then discharged from the hospital after three days of treatment and was being monitored in outpatient clinic.

## DISCUSSION

The diagnosis of PPCM is a diagnosis of exclusion. The physician needs to exclude other etiologies of heart failure in the patient. Initial history taking is essential to collect the data of any pre-existing cardiac dysfunction, whether during or before the pregnancy. Patients with PPCM may present with dyspnea, orthopnea, edema, palpitation, and impairment of activity.<sup>6</sup> To establish the diagnosis, the physician should conduct an echocardiography examination. ECG can also be performed at the beginning.

ECG is an easily accessible and safe tool to evaluate the patients. Several patterns could appear such as inversion of T-wave and bundle branch block. T-wave inversion is more common than the other pattern and is negatively correlated with the systolic function ( $p= 0.03$ ). T-wave inversion pattern at the baseline is also associated with a persistent systolic dysfunction until six months after the first diagnosis.<sup>7</sup> The ECG of our patient also showed a pattern of LBBB, which is a sign of cardiomyopathy.<sup>8</sup> Echocardiography is important in examining the left ventricular ejection fraction (LVEF). In PPCM cases, we would find the LVEF to be  $< 45\%$ . Echocardiography is able to find a dilatation of the chamber and M-mode fractional shortening  $<30\%$ .<sup>9,10</sup> Mitral regurgitation may appear in PPCM due to left ventricular dilation.<sup>11</sup> Echocardiography is also capable to exclude other diagnosis. Patients who present with diastolic dysfunction but with good systolic function should be suspected to have preeclampsia.<sup>12</sup>

Furthermore, these several criteria can be used in making the diagnosis of PPCM. The criteria include the presence of left ventricular systolic dysfunction from echocardiography examination in the peripartum period, the onset of the symptoms during the last month of pregnancy and 5 months post-partum, no other etiologies

of heart failure, and no evidence of heart disease before the last month of pregnancy.<sup>9</sup>

Diuretic should always be prepared to be administered to PPCM patients especially in emergency settings. Two types of diuretic, loop and thiazide, were recommended as the initial treatment for moderate and severe PPCM patient.<sup>13</sup> Both are considered to be safe during pregnancy but there is a very limited data on furosemide usage during lactation.<sup>14</sup> We initiated furosemide IV drip in this patient because the patient did not breastfeed.

Norepinephrine is recommended to be the first-line treatment for patient with classic wet and cold presentation while dobutamine is added when the patient stabilizes.<sup>15</sup> However, the recommendation can be considered to oversimplify the management of cardiogenic shock in clinical practice because the treatment should not only be focused on improving blood pressure. A review conducted recommended that there are three aspects that should be assessed in treating patient with cardiogenic shock which are metabolic optimization, pump function optimization, and tissue perfusion optimization.<sup>16</sup> The main problem within the patient was the inadequate left ventricle contractility so that we administered dobutamine to optimize the pump function. However, since the administration of maximum dose dobutamine did not improve the blood pressure, we added norepinephrine. Currently, there is no study that directly compared the efficacy and safety of dobutamine and norepinephrine combination to dobutamine in heart failure patient, let alone in PPCM patient. A study conducted by Levy B et al concluded that epinephrine was as effective as the combination of norepinephrine and dobutamine in improving global hemodynamic effect of cardiogenic shock patients, but the combination was more reliable and safer.<sup>17</sup>

The existing guideline in the management of PPCM by ESC based on multiple trials suggested that bromocriptine should be given in PPCM patients with any severity. The treatment is differentiated into two groups: the uncomplicated patients (1 week treatment, 2.5 mg once daily) and complicated patients with EF  $<25\%$ , right ventricular involvement, intensive care treatment, and/or cardiogenic shock (2.5 mg twice daily for two weeks and 2.5 mg once daily for 6 weeks).<sup>15</sup> Therefore, we prescribed the patient with bromocriptine for 8 weeks. In addition to bromocriptine, we added ramipril and

bisoprolol as regular oral HF drugs. ACE-inhibitor is suggested to be given to patient that did not breastfeed and contraindicated to be given in pregnant patient, while beta-blockers should be prescribed to all PPCM patients (pregnant or after delivery).<sup>15</sup>

### CONCLUSION

Peripartum cardiomyopathy is a rare condition in daily practice, yet causes a high mortality rate. It may not be easy to diagnose because the symptoms are not specific and may present in normal pregnancy. Good history taking and diagnostic testing may help to make the diagnosis. Echocardiography is an important tool to evaluate the cardiac function and rule out the other cause of cardiomyopathy. Proper management can improve the clinical symptoms and improve the cardiac function.

### REFERENCES

1. Koenig T, Hilfiker-Kleiner D, Bauersachs J. Peripartum cardiomyopathy. *Herz*. 2018;43(5):431-7.
2. Hilfiker-Kleiner D, Haghikia A, Nonhoff J, Bauersachs J. Peripartum cardiomyopathy: current management and future perspectives. *Eur Heart J*. 2015;36(18):1090-7.
3. Kolte D, Khera S, Aronow WS, Palaniswamy C, Mujib M, Ahn C, et al. Temporal trends in incidence and outcomes of peripartum cardiomyopathy in the United States: a nationwide population-based study. *J Am Heart Assoc*. 2014;3(3):e001056.
4. Karaye KM, Sa'idu H, Balarabe SA, Ishaq NA, Adamu UG, Mohammed IY, Oboirien I, Umuerrri EM, Mankwe AC, Shidali VY, Njoku P, Dodiya-Manuel S, Olunuga T, Josephs V, Mbakwem AC, Okolie H, Talle MA, Isa MS, Ogah OS, Stewart S; PEACE Registry Investigators. Clinical Features and Outcomes of Peripartum Cardiomyopathy in Nigeria. *J Am Coll Cardiol*. 2020 Nov 17;76(20):2352-2364.
5. Wu VC, Chen TH, Yeh JK, Wu M, Lu CH, Chen SW, et al. Clinical outcomes of peripartum cardiomyopathy: a 15-year nationwide population-based study in Asia. *Med (Baltimore)*. 2017;96(43):e8374.
6. Azibani F, Sliwa K. Peripartum Cardiomyopathy: an Update. *Curr Heart Fail Rep*. 2018;15(5):297-306.
7. Tibazarwa K, Lee G, Mayosi B, Carrington M, Stewart S, Sliwa K. The 12-lead ECG in peripartum cardiomyopathy. *Cardiovascul J Afr*. 2012;23(6):322-9.
8. Labidi S, Hilfiker-Kleiner D, Klein G. Left bundle branch block during pregnancy as a sign of imminent peripartum cardiomyopathy. *Eur Heart J*. 2011;32(9):1076.
9. Okeke T, Ezenyeaku C, Ikeako L. Peripartum cardiomyopathy. *Ann Med Health Sci Res*. 2013;3(3):313-9.
10. Bhattacharyya A, Basra SS, Sen P, Kar B. Peripartum cardiomyopathy: a review. *Tex Heart Inst J*. 2012;39(1):8-16.
11. Bollen IA, Van Deel ED, Kuster DW, Van Der Velden J. Peripartum cardiomyopathy and dilated cardiomyopathy: different at heart. *Front Physiol*. 2015;5:531.
12. Kim MJ, Shin MS. Practical management of peripartum cardiomyopathy. *Korean J Intern Med*. 2017;32(3):393-403.
13. Bauersachs J, König T, Meer P Van Der, et al. Pathophysiology, diagnosis and management of peripartum cardiomyopathy: a position statement from the Heart Failure Association of the European Society of Cardiology Study Group on peripartum cardiomyopathy. *Eur J Heart Fail*. 2019;21:827-3.
14. Hilfiker-kleiner D, Haghikia A, Nonhoff J, Bauersachs J. Clinical update Peripartum cardiomyopathy: current management and future perspectives. *Eur Heart J*. 2015;36:1090-7.
15. van Diepen S, Katz JN, Albert NM, et al. Contemporary Management of Cardiogenic Shock. *Circul*. 2017;136:e232-e8.
16. Squara P, Hollenberg S, Payen D. Reconsidering Vasopressors for Cardiogenic Shock Everything Should Be Made as Simple as Possible, but Not Simpler. *Chest*. 2019;156(2):392-401.
17. Levy B, Perez P, Perny J, Thivillier C, Gerard A. Comparison of norepinephrine-dobutamine to epinephrine for hemodynamics, lactate metabolism, and organ function variables in cardiogenic shock. A prospective, randomized pilot study. *Crit Care Med*. 2011;39(3):450-5.