

## Case Report

## Role of Ambulatory Laparoscopy in Diagnosis of Ascites with Unknown Etiology

### *Peran Laparoscopi dalam Mendiagnosis Asites akibat Etiologi yang tidak Diketahui*

Herbert Situmorang<sup>1</sup>, Raymond Surya<sup>1</sup>, Tantri Hellyanti<sup>2</sup>

<sup>1</sup>Department of Obstetrics and Gynecology

<sup>2</sup>Department of Pathology Anatomy  
Faculty of Medicine Universitas Indonesia  
Dr. Cipto Mangunkusumo General Hospital  
Jakarta

#### Abstract

**Objective:** To determine the evidence about timing and role of laparoscopy in ascites work-up.

**Methods:** : Case report

**Case:** A-26-year-old P2 woman went to our hospital with a history of vaginal delivery 22 days before admission. She also presented with massive ascites. No obstetric complication was found. Transvaginal ultrasound revealed normal postpartum uterus and ovaries, surrounded with ascites. Both the liver and kidneys were found normal on ultrasound. Abdominal CT scan with contrast showed massive ascites with thickened omentum. Ascites ADA (adenosine deaminase) was 36 IU/L. Diagnostic laparoscopy was performed, we found massive yellowish ascites, miliary whitish lesions and hyperaemic tubal enlargement with thickening of the peritoneum. Biopsy was taken, pathology examination showed the appearance of chronic salpingitis and granulomatous peritonitis, in accordance with tuberculosis peritonitis.

**Conclusions:** Laparoscopy should be the method of choice in diagnosing ascites with unknown etiology after inconclusive results of laboratory and radiological examination. Better visualization, typical appearance in peritoneal TB, chance to perform direct biopsy with lower risk of morbidity are the hallmarks of laparoscopy to be the method of choice to rule out the etiology of ascites.

**Keywords:** ascites, laparoscopy, peritoneal tuberculosis.

#### Abstrak

**Tujuan:** Untuk mengetahui bukti tentang waktu dan peran laparoscopi dalam penegakan diagnosis asites.

**Metode:** Laporan kasus

**Kasus:** Seorang perempuan 26 tahun para 2 datang dengan riwayat persalinan pervaginam 22 hari lalu datang dengan asites masif. Tidak ada komplikasi obstetri yang ditemukan. Pemeriksaan ultrasonografi transvaginal memperlihatkan uterus dan ovarium normal sesuai postpartum dikelilingi dengan asites. Kedua hati dan ginjal dalam batas normal. CT scan abdomen dengan kontras memperlihatkan asites masif dengan penebalan omentum. ADA (adenosine deaminase) di cairan asites 36 IU/L. Kami memutuskan melakukan laparoscopi diagnostik dan biopsi. Kami menemukan asites masif berwarna kekuningan dan pembesaran tuba hiperemis dengan penebalan peritoneum. Pemeriksaan patologi memperlihatkan salpingitis kronik dan peritonitis granulomatosa sesuai dengan peritonitis TB.

**Kesimpulan:** Laparoscopi merupakan metode pilihan dalam mendiagnosis asites dengan etiologi yang tidak diketahui jika hasil laboratorium dan pemeriksaan radiologis meragukan. Visualisasi yang lebih baik, penampilan khas TB peritoneum, kesempatan untuk melakukan biopsi langsung dengan risiko morbiditas yang lebih rendah adalah ciri utama laparoscopi sebagai metode pilihan untuk mendiagnosis etiologi asites.

**Kata kunci:** asites, laparoscopi, tuberkulosis peritoneal.

**Correspondence author.** Herbert Situmorang. Department of Obstetrics and Gynecology  
Faculty of Medicine Universitas Indonesia. Jakarta. herbert.situmorang@ui.ac.id

## INTRODUCTION

Ascites is a pathological accumulation of fluid in the peritoneal cavity. It can be caused by several pathophysiology mechanism such as portal hypertension (75%), malignancy (10%), heart failure (3%), tuberculosis (TB) (1%), and pancreatitis (1%).<sup>1</sup> Diagnostic approach of patient with ascites consists of history, physical examination, blood test, abdominal ultrasound, ascitic fluid analysis through visual inspection, biochemical testing (serum ascites albumin gradient, total protein, amylase, triglycerides, adenosine deaminase (ADA), glucose and lactate dehydrogenase, urea and creatinine), and non-biochemical testing (polymorphonuclear leukocyte count, bacterial cultures, PCR bacterial DNA, cytology), also diagnostic laparoscopy.<sup>2</sup>

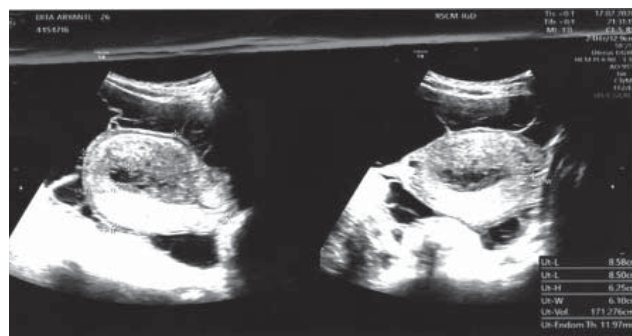Diagnostic laparoscopy offers advantages of direct visualization of peritoneal cavity in combination with ability to obtain targeted biopsy for histological and microbiological studies. It is helpful to determine the diagnosis of peritoneal carcinomatosis, TB peritonitis, and other peritoneal or omental diseases such as mesothelioma and sclerosing peritonitis.<sup>3</sup> However, laparoscopy techniques are not absolutely risk free. It may be associated with injuries to bowel, solid organ, major blood vessels with failure rate up to 14% owing to adhesion of primary illness or former surgery.<sup>4,5</sup> Currently, laparoscopy has wide application and it has made a revolution in gastroenterology, gynecology, and urological surgeries. Therefore, this case report would like to highlight the ability of laparoscopy in unknown ascites origin which has been performed several laboratories work up.

## CASE

A-26-year-old P2 woman came to hospital with a history of vaginal delivery 22 days before admission presenting with massive ascites, anemia (Hb 8.1 g/dL), and malnutrition. Patient complained of abdominal enlargement for 2 weeks. There was no history of hypertension in pregnancy, liver disease such as hepatitis B, chronic cough, bloody cough, night sweats or decrease of body weight. On physical examination, we found tachycardia with heart rate 120 bpm and normal body temperature. The body mass index (BMI) was 17.6 kg/m<sup>2</sup> (underweight) with upper arm circumference was 20 cm. On physical examination, there was

shifting dullness suggesting massive ascites with bilateral non-pitting oedema. Obstetrical status was within normal limits.

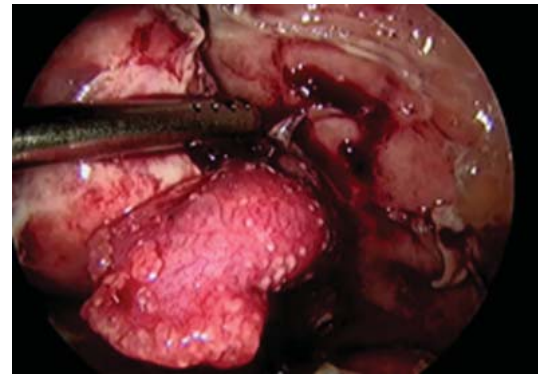
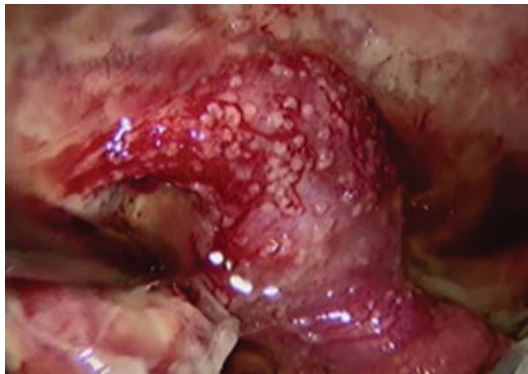Abdominal and vaginal ultrasound showed a postpartum uterus with a small amount of blood clot inside the cavity. There was ascites with fibrins surrounding the pelvic and abdominal cavity suggesting signs of infection (figure 1). Liver and both kidneys were normal. Laboratory examination revealed an increase of Ca-125 level (513.6 U/mL), negative result for HIV and HbsAg. The chest X-ray showed minimal left pleural effusion, infiltrate at supra-hilar and lower lobe of left lung suspected pneumonia. Abdominal CT scan with contrast presented hepatosplenomegaly, calcification lesion at anterior mesentery abdomen sized 0.9 cm suspected lymphadenopathy, and massive ascites with thickened omentum. We performed ascites puncture; coming out 2 litres of yellowish ascites and sent it for ascites analysis, cytology, acid fast and gram staining, and adenosine deaminase (ADA). Ascites analysis was considered as exudate with serum-ascites albumin gradient or gap (SAAG) 0.8. Result of cytology was mesothelial, macrophage, and leucocyte, no malignant tumour cell found. Acid fast bacilli and gram staining showed negative results and ADA was 36 IU/L (normal range <30 U/L).



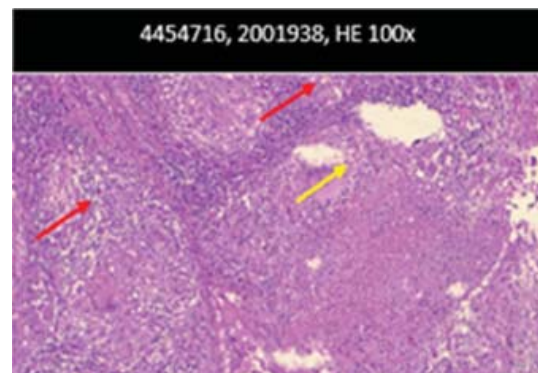
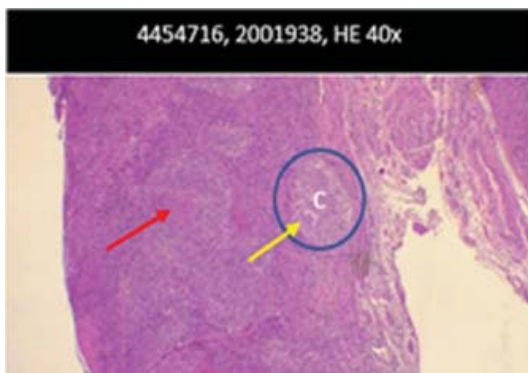
**Figure 1.** Gynecological ultrasound of patients showing fibrin covered uterus

We decided to perform diagnostic laparoscopy and biopsy for histopathology. We found massive yellowish ascites (2300 mL), uterus was covered by fibrin, left tube was enlarged, and left ovary was normal. On the right tube, there were papules on surfaces; meanwhile, the right ovary was normal. We performed left salpingectomy and took histopathology specimen from peritoneal wall. We could not visualize the appendix and liver because there was adhesion between intestine and peritoneal wall (figure 2). Pathology anatomy result showed

chronic salpingitis and granulomatous peritonitis consistent with tuberculosis peritonitis (figure 3 and 4). Therefore, the final diagnosis was massive ascites due to peritoneal and salpingitis tuberculosis; the patient got nine months of anti-tuberculous drug.



**Figure 2.** Laparoscopic finding: whitish and miliary nodules on left tube and peritoneal wall



**Figure 3.** Histopathology from Fallopian tube specimens

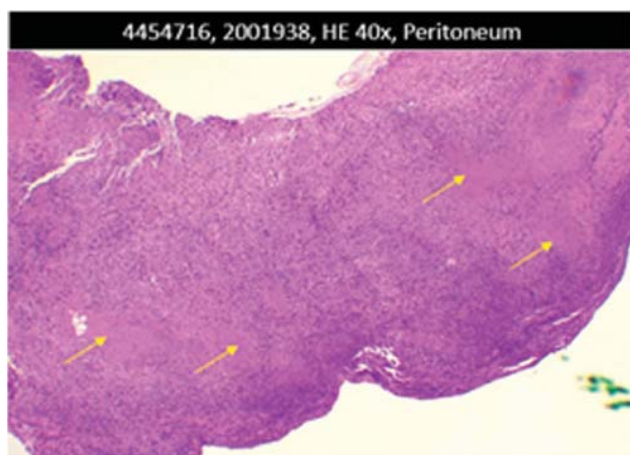
Caseous necrosis (red arrow) was found as part of granuloma (blue circle). Granuloma was surrounded with rim of lymphocytes (yellow arrow) Caseous necrosis (yellow arrow) was found in many areas.

**Problem**

In exudative ascites with unknown origin, how important is laparoscopy to differentiate peritoneal TB and other causes of ascites?

**Searching strategy**

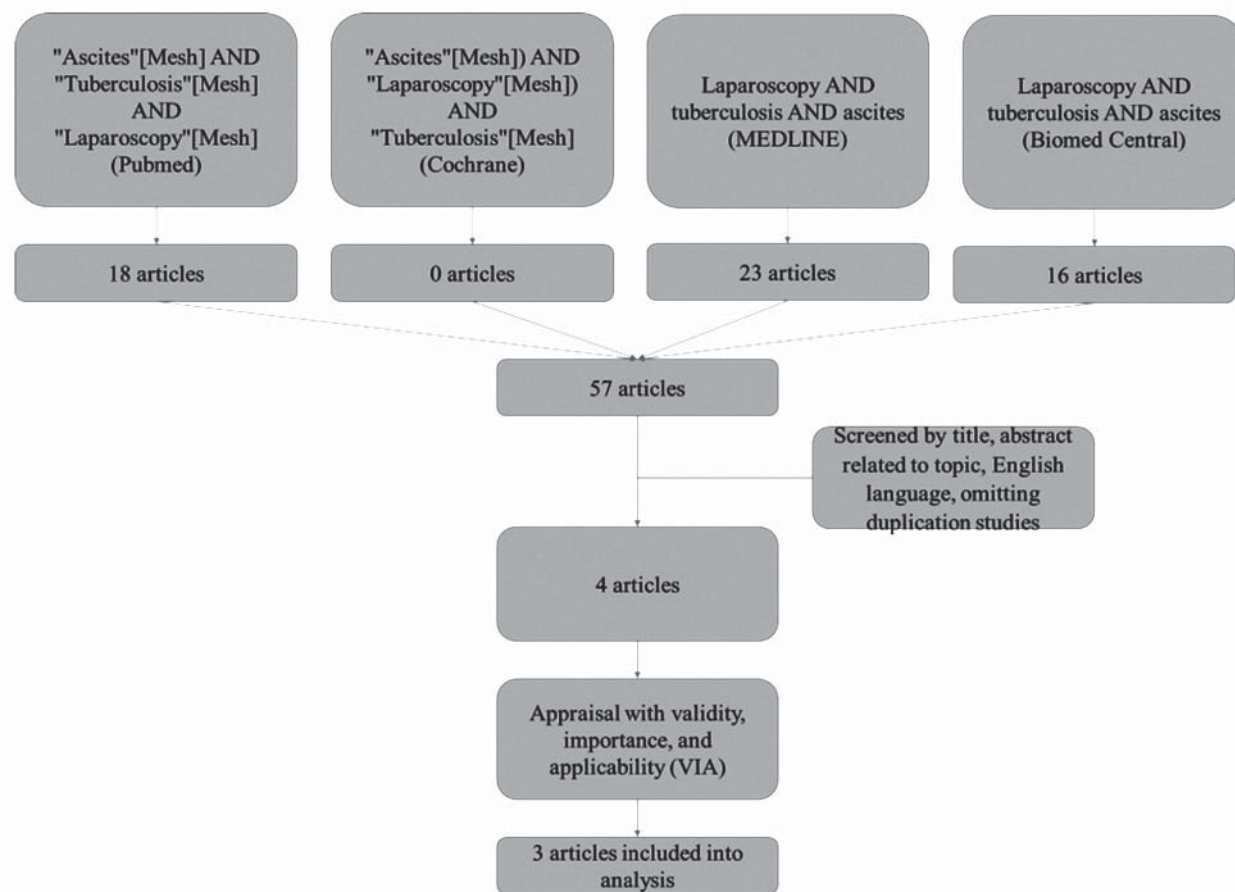
To answer the clinical question, the search was conducted on Pubmed®, Cochrane Library®, Medline®, and Biomed Central®. In Pubmed, the search included keywords using the MeSH, namely "Ascites" AND "Tuberculosis" AND "Laparoscopy". Meanwhile, in Cochrane, the MeSH descriptor consisted of "Ascites" AND "Laparoscopy" AND "Tuberculosis". The author used keywords of ascites AND laparoscopy AND tuberculosis both in Medline and Biomed Central. From the searching strategy above performed on March 19th 2020, there were 18, 0, 16, and 23 studies in Pubmed®, Cochrane Library®,



**Figure 4.** Histopathology of the peritoneum

Medline®, and Biomed Central® database; respectively. The articles were screened using the criteria consisting of abstracts answering the clinical question, written in English language, full-text paper availability, and omitting all duplication papers. After screening, there were 4 articles

appropriate to the inclusion criteria. Critical appraisal determining the validity, importance, and applicability (VIA) was conducted by 2 independent authors. The critical appraisal steps used in this article was written. The flowchart of searching strategy was shown at figure 4<sup>6-9</sup>



### Searching Results

We conducted appraisal to 4 studies according to VIA criteria based on diagnostic study by Centre for Evidence-Based Medicine, University of Oxford, 2010. These consisted of two cross-sectional and two cohort studies. From diagnostic appraisal form, two studies did not show blind randomization and all studies did not validate in an independent group of patients. For importance, one study did not show the importance because only one case was performed laparoscopy.<sup>7</sup>

Other studies did not reveal the sensitivity and specificity of laparoscopy in peritoneal TB. They recruited samples starting from peritoneal TB patients presenting with ascites. They did not perform laparoscopy on peritoneal TB patients without ascites. Thus, there was only either positive rate or PPV of laparoscopy. For applicability, all studies can be applied in our patient because ambulatory laparoscopy for ascites work-up is available in our institution. Table 1 showed the result of appraisal diagnostic studies.

**Table 1.** Result of Diagnostic Appraisal Studies

Study	Validity				Importance	Available, affordable, accurate, and precise	Applicability Estimate patient's pre-test probability	Post-test probabilities affect management
	Blind comparison	Appropriate spectrum of patient	Reference standard applied	Validated in an independent group of patients				
<b>Demir K, et al</b>	No	Yes	Yes	No	Positive rate of laparoscopy: 24/25 (96%)	Yes	Yes	Yes
<b>Vardareli E, et al</b>	Yes	Yes	Yes	No	N/A			
<b>Bedioui H, et al</b>	Yes	Yes	Yes	No	PPV of laparoscopy: 85%	Yes	Yes	Yes
<b>Huang B, et al</b>	No	Yes	Yes	No	Positive rate of laparoscopy: 43/51 (84.31%)	Yes	Yes	Yes

## DISCUSSION

Ascites as an accumulation of fluids inside abdominal cavity is a sequelae of an illness which can come from local peritoneal or systemic disease.<sup>10</sup> Commonly, gradual painless accumulation of ascitic fluid is indicative of chronic benign condition while rapid accumulation and weight loss belong to malignant condition.<sup>11</sup> Routine laboratory test such as chemical examination of ascites fluid can help to diagnosis the original cause of ascites in most cases. Radiological tools are the last non-invasive way to determine etiology with limitations in some cases. In inconclusive laboratory and radiology tests, diagnostic laparoscopy with direct visualization of peritoneal cavity is mandatory to solve this problem and distinguish the origin of ascites.<sup>12</sup>

In our case, under laparoscopic view, there were papules on the surface of the right fallopian tube and adhesion between the peritoneal wall and intestine suspected to be peritoneal TB, confirmed with pathology examination. Peritoneal TB had an incidence of 0.5-1.5% and prevalence of 4-10% within cases of extra-pulmonary TB.<sup>13</sup> Most reported cases with peritoneal TB are frequently related with AIDS, liver cirrhosis, alcohol intake, poverty, and malnutrition.<sup>14</sup> The symptoms can be varied. The most common signs of peritoneal TB were abdominal mass (80.77%) followed by ascites (57.69%) and abdominal distention (57.69%).<sup>15</sup> These signs were not specific and can be mimicking as occult malignancy or cirrhosis.<sup>7</sup>

Imaging techniques such as CT scan and MRI have limited efficacy to diagnosis peritoneal TB due to non-specific. CT scan may show generalized or localized ascites with thin mobile septa, thick omentum and peritoneum, lymphadenopathy, or thickened bowel. In our case, the abdominal CT revealed hepatosplenomegaly, calcification lesion at anterior mesentery abdomen sized 0.9 cm suspected lymphadenopathy, and massive ascites with omentum thickening. It is not specific as common findings of abdominal CT in peritoneal TB: smooth, strongly enhancing peritoneal thickening, a nodular or caked omentum, dense ascites, caseous nodes, soft tissue mesenteric, and omental infiltration.<sup>16</sup> Some studies supported PET-CT as non-invasive method to diagnose peritoneal TB, especially to differentiate with peritoneal carcinomatosis;<sup>17,18</sup> while others did not because of its high cost.<sup>15,19</sup> A study did a cost analysis of a peritoneal TB patients who underwent PET-CT scan had similar hospital expenses that performed surgery.<sup>15</sup>

Analysis of ascitic fluid is an important step in diagnosing ascites. In our case, the cytology, acid fast bacilli, and gram staining showed negative results. It raises the challenge for diagnostic difficulties due to the poor predictive value of those tests and low positive bacteriological rate on cytology which only 3% of positive results on direct examinations. Time needed for culture is more than two months for positive results in less than 35% of cases.<sup>20</sup> Polymerase chain reaction (PCR) of ascites for mycobacterium can be considered for diagnosis; however, it

is not widely available. PCR test could reach a sensitivity of 85% in smear-positive patients; however, it falls to 45% in negative smears.<sup>20</sup> Adenosine deaminase (ADA) as purine degrading enzyme is distributed in tissue and body fluid. It is necessary for T lymphocytes proliferation and differentiation as an immune cellular mechanism against *M. Tuberculosis*. Ascites ADA at cut-off level of 21.0 IU/L has the strongest factor to differentiate peritoneal TB and peritoneal carcinomatosis with good sensitivity, specificity, positive predictive value and negative predictive value (92.0%, 94.4%, 95.8%, 89.5%).<sup>21</sup> Another study stated that ascites ADA above 39 IU/L was reliable to diagnose peritoneal tuberculosis with 100% sensitivity and 97.2% specificity.<sup>22</sup> ADA in our study was 36 IU/L which meant approaching the cut off value of diagnosing peritoneal TB. In this circumstance, laparoscopy is needed to confirm the diagnosis.<sup>23</sup>

Laparoscopy is preferred over laparotomy due to its well-known minimal invasive advantages. It allows not only inspection of peritoneum, but also obtaining specimens for histology with lower risk of surgical morbidity.<sup>15,24</sup> Positive appearance of TB in 96% of cases<sup>6</sup>. This includes scattered or confluent multiple, whitish, miliary nodules (<5 mm) over the visceral and parietal peritoneum, adhesion, thickened and hyperemic peritoneum, and turbid ascites. Only one patient showed no signs of peritoneal TB despite histologic examination revealed it. In this study, no complications were found during and after laparoscopy. Reported 18 patients underwent image-guided percutaneous peritoneal biopsy (IGPB). This percutaneous biopsy has limited sensitivity as it is performed blindly, also tissue samples are usually small.<sup>7</sup>

In inconclusive ascites workup, laparoscopy and directed biopsy can establish the diagnosis in 80-95% of cases.<sup>7,25</sup> Studied 90 cases of isolated exudative ascites explored laparoscopically and found 59 cases of peritoneal TB. The gross aspect of abdominal cavity at laparoscopy was typical in 90% of patients with confirmed tuberculosis. The PPV of TB by laparoscopy was 85%. The pathology examination of peritoneal biopsy to confirm the peritoneal tuberculosis was 58 out of 59 patients (98%). Peritoneal biopsy with laparoscopy is better because of direct visualization and higher quality of specimens obtained. Laparoscopy had lower risk of morbidity and zero mortality outside risk of anesthesia and surgery.<sup>8,23</sup>

As explained above, the standard of TB

diagnosis worldwide is via culture of involved organism. However, this method has significant disadvantage that it consumes longer time to acquire the result. Another alternative tool includes the use of molecular diagnostic method such as PCR; nevertheless, it is not readily available, especially in rural area.<sup>20</sup> A different substitute is to assess peritoneal TB is to measure the level of ascites ADA. For own case, this method was still inconclusive because the cut off is 39 IU/L (100% sensitivity and 97.2% specificity)<sup>22</sup> Therefore, this case reported use of ambulatory laparoscopy as a choice to diagnose peritoneal TB.

## CONCLUSION

Laparoscopy should be the method of choice in diagnosing ascites with unknown etiology after inconclusive results of laboratory and radiological examination. Better visualization, typical appearance in peritoneal TB, chance to perform direct biopsy with lower risk of morbidity are the hallmarks of laparoscopy to be the method of choice to rule out the etiology of ascites.

## REFERENCES

1. Garcia-Tsao G. Ascites. In: *Sherlock's Diseases of the Liver and Biliary System* [Internet]. John Wiley & Sons, Ltd; 2018: 127–50. <https://onlinelibrary.wiley.com/doi/abs/10.1002/9781119237662.ch9>
2. Oey RC, van Buuren HR, de Man RA. The diagnostic work-up in patients with ascites: current guidelines and future prospects. *Neth J Med*. 2016 ;74(8):330–5.
3. Han C-M, Lee C-L, Huang K-G, Chu C-M, Lin S-M, Wang C-J, et al. Diagnostic laparoscopy in ascites of unknown origin: Chang Gung Memorial Hospital 20-year experience. *Chang Gung Med J*. 2008 ;31(4):378–83.
4. Wani M, Mir SA, Bhat JA, Moheen HA. Ancillary tests to improve the accuracy of laparoscopy in the diagnosis of tuberculous peritonitis. *Can J Surg*. 2014 ;57(2):E54.
5. Vilos GA, Ternamian A, Dempster J, Laberge PY, CLINICAL PRACTICE GYNAECOLOGY COMMITTEE. Laparoscopic entry: a review of techniques, technologies, and complications. *JOGC*. 2007 ;29(5):433–47.
6. Demir K, Okten A, Kaymakoglu S, Dincer D, Besik F, Cevikbas U, et al. Tuberculous peritonitis--reports of 26 cases, detailing diagnostic and therapeutic problems. *Eur J Gastroenterol Hepatol*. 2001 ;13(5):581–5.
7. Vardareli E, Kebapci M, Saricam T, Pasaoglu O, Açikalin M. Tuberculous peritonitis of the wet ascitic type: clinical features and diagnostic value of image-guided peritoneal biopsy. *Dig Liver Dis Off J Ital Soc Gastroenterol Ital Assoc Study Liver*. 2004 ;36(3):199–204.
8. Bedioui H, Ksantini R, Nouira K, Mekni A, Daghfous A, Chebbi F, et al. Role of laparoscopic surgery in the etiologic diagnosis of exudative ascites: a prospective study of 90 cases. *Gastroenterol Clin Biol*. 2007;31(12):1146–9.

9. Huang B, Cui DJ, Ren Y, Han B, Yang DP, Zhao X. Comparison between laparoscopy and laboratory tests for the diagnosis of tuberculous peritonitis. *Turk J Med Sci.* 2018 ;48(4):711–5.
10. Wei C, Xiong F, Yu Z-C, Li D-F, Luo M-H, Liu T-T, et al. Diagnosis of follicular lymphoma by laparoscopy: A case report. *World J Clin Cases.* 2019 ;7(8):984–91.
11. Boussios S, Moschetta M, Karathanasi A, Tsiouris AK, Kanellos FS, Tatsi K, et al. Malignant peritoneal mesothelioma: clinical aspects, and therapeutic perspectives. *Ann Gastroenterol.* 2018;31(6):659–69.
12. - Abdelkader A, - Zaher N, - Mitwally R, - Hassanien S, - Dawa S. The role of laparoscopy in the diagnosis of ascites of unknown etiology. *Egy J Surg.* 38(4):760.
13. Al-Mulhim AA. Laparoscopic diagnosis of peritoneal tuberculosis. *Surg Endosc.* 2004 ;18(12):1757–61.
14. Pop M, Pop C, Homorodean D, Itu C, Man M, Goron M, et al. Abdominal miliary tuberculosis in a patient with AIDS: a case report. *Roma J Gastroenterol.* 2003 ;12(3):231–4.
15. Wang H, Qu X, Liu X, Ding L, Yue Y. Female Peritoneal Tuberculosis with Ascites, Pelvic Mass, or Elevated CA 125 Mimicking Advanced Ovarian Cancer: A Retrospective Study of 26 Cases. *J Coll Physicians Surg Pak JCPSP.* 2019 ;29(6):588–9.
16. Lee W-K, Van Tonder F, Tartaglia CJ, Dajia C, Cazzato RL, Duddalwar VA, et al. CT appearances of abdominal tuberculosis. *Clin Radiol.* 2012 ;67(6):596–604.
17. Wang S-B, Ji Y-H, Wu H-B, Wang Q-S, Zhou W-L, Lv L, et al. PET/CT for differentiating between tuberculous peritonitis and peritoneal carcinomatosis. *Medicine (Baltimore)* <https://www.ncbi.nlm.nih.gov/pmc/articles/PMC5266185/>
18. Castaigne C, Garcia C, Flamen P. Tuberculosis on FDG PET-CT: The great imitator. *J Nucl Med.* 2014 1;55(suppl 1):1969.
19. Sharma JB, Jain SK, Pushparaj M, Roy KK, Malhotra N, Zutshi V, et al. Abdomino-peritoneal tuberculosis masquerading as ovarian cancer: a retrospective study of 26 cases. *Arch Gynecol Obstet.* 2010 ;282(6):643–8.
20. Sanai FM, Bzeizi KI. Systematic review: tuberculous peritonitis--presenting features, diagnostic strategies and treatment. *Aliment Pharmacol Ther.* 2005 15;22(8):685–700.
21. Kang SJ, Kim JW, Baek JH, Kim SH, Kim BG, Lee KL, et al. Role of ascites adenosine deaminase in differentiating between tuberculous peritonitis and peritoneal carcinomatosis. *World J Gastroenterol .* 2012 ;18(22):2837–43.
22. Ali N, Nath NC, Parvin R, Rahman A, Bhuiyan TM, Rahman M, et al. Role of ascitic fluid adenosine deaminase (ADA) and serum CA-125 in the diagnosis of tuberculous peritonitis. *Bangl Med Res Counc Bull.* 2014 ;40(3):89–91.
23. Târcoveanu E, Dimofte G, Bradea C, Lupaşcu C, Moldovanu R, Vasilescu A. Peritoneal tuberculosis in laparoscopic era. *Acta Chir Belg.* 2009; 109(1):65–70.
24. Fahmi MN, Harti AP. A diagnostic approach for differentiating abdominal tuberculosis from ovarian malignancy: a case series and literature review. *BMC Proc.* 2019 ;16;13(11):13.
25. Sotoudehmanesh R, Shirazian N, Asgari AA, Malekzadeh R. Tuberculous peritonitis in an endemic area. *Dig Liver Dis.* 2003 ;35(1):37–40.