

Literature Review

## Purse String Double Layer Closure in Cesarean Section (Turan Technique) : A Novel Approach to Reduce Cesarean Scar Defect

### *Teknik Turan (Penjahitan Dua Lapis Purse String): Pendekatan Terkini untuk Menurunkan Defek Jaringan Parut Bekas Seksio Sesarea*

Aditya Prabawa, A A Ngurah Jayakusuma, A A Gede P. Wiradnyana

Department of Obstetrics and Gynecology  
Faculty of Medicine Universitas Udayana  
Sanglah General Hospital  
Bali

#### Abstract

**Objective:** To compare cesarean scar defect incidence and other parameters between Turan technique and Conventional technique.

**Methods:** Literature Review

**Results:** The Turan technique uses a purse-string double-layer closure method, which can shorten the incision length and reduce the incidence of postpartum cesarean scar defect that can be detected by ultrasound. Uterine incisional defects are etiologic factors of postoperative pelvic adhesion, placenta previa and accreta, uterine rupture, abnormal uterine bleeding and dysmenorrhea. This means that a decrease in the incidence of uterine incisional defects is essential to prevent cesarean-related complications. In 51 patients in the study group (closure the uterine incision with Turan technique) and 65 patients in the control group collected within six weeks postoperative for transvaginal ultrasound, the length of the uterine incision closure in the study group shorter than the control group ( $p = 0.0001$ , 95% IK = 2,854-6,876). Significantly, the number of patients with cesarean scar defect was 12 (23.5%) in the study group and 39 in the control group (76.5%) with  $P = 0.0001$ .

**Conclusions:** Turan technique is new uterine closure method technique on CS. This technique can reduce the incidence of cesarean scar defect.

**Keywords:** cesarean section, turan technique, uterine incision.

#### Abstrak

**Tujuan:** Untuk membandingkan angka kejadian defek jaringan parut uterus dan parameter lain antara teknik Turan dan teknik konvensional.

**Metode:** Kajian Pustaka

**Hasil:** Teknik Turan menggunakan metode penutupan purse-string double layer, di mana dapat memperpendek insisi dan mengurangi insidensi defek jaringan parut uterus postpartum yang dapat dideteksi dengan ultrasonografi. Defek insisional uterus merupakan faktor etiologi dari adhesi pelvis pasca operasi, plasenta previa dan akreta, ruptur uteri, kehamilan ektopik pada parut uterus, perdarahan uterus abnormal dan dismenore. Ini berarti penurunan kejadian defek insisional uterus sangat penting untuk mencegah terjadinya komplikasi terkait seksio sesarea. Pada 51 pasien kelompok studi (teknik Turan) dan 65 pasien pada kelompok kontrol yang dilakukan pemeriksaan ultrasonografi transvaginal 6 minggu pascaoperasi didapatkan data bahwa panjang insisi uterus lebih pendek pada kelompok studi ( $p = 0.0001$ , 95% IK = 2.854-6.876). Secara signifikan, jumlah pasien dengan defek parut bekas operasi (Cesarean Scar Defect) adalah 12 orang (23.5%) pada kelompok studi dan 39 orang pada kelompok kontrol (76.5%) dengan nilai  $p = 0.0001$ .

**Kesimpulan:** Teknik Turan adalah teknik baru mengenai metode penjahitan pada insisi operasi SC. Secara signifikan tehnik ini mampu menurunkan insidensi defek parut bekas operasi.

**Kata kunci:** insisi uterus, seksio sesarea, teknik turan.

Correspondence author. Aditya Prabawa. adityaprabawa2@gmail.com

## INTRODUCTION

Almost all women in the world will experience pregnancy and delivery. Labour is physiological process on human life. One mode of delivery is cesarean section (CS). To date, there are no data that provide the best operating CS techniques.<sup>1</sup> Some CS techniques have been done routinely, for example, one-layer, two-layer and uterine closure techniques with different stitches and incisions.<sup>2,3</sup> These techniques have been associated with long-term risks such as postoperative pelvic adhesion, uterine rupture and placental complications such as placenta previa and placenta accreta.<sup>4,5</sup> Consideration should be given to techniques for the closure of the uterine incision that are capable provide benefit and minimize risk of uterine damage. Currently, purse strings double-layer uterine closure technique (Turan technique) has been considered as technique of CS incision closure that can reduce level of uterine tissue damage. The length of the uterine incision closure becomes shorter, less of bleeding and minimal cesarean scar defect.<sup>5</sup> Expected no short-term and long-term complications that can occur in patients. Turan technique with purse-string double-layer closure principle, which can shorten incision closure length and reduce the rate of occurrence of cesarean scar defect detectable by transvaginal ultrasound. A significant decrease of uterine incisional defects in patients undergoing cesarean section by Turan technique compared to the double layer uterine closure technique.

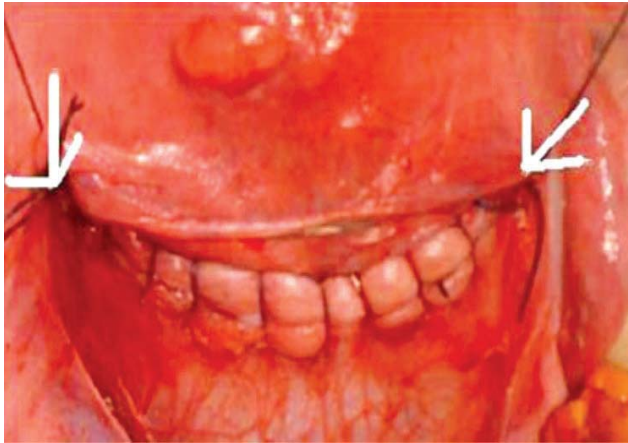## RESULTS

Cesarean scar defect is dehiscence followed by a discontinuity in the location of the previous myometrium scar. CS procedure may be associated with many clinical problems such as ectopic pregnancy at the CS scar, uterine rupture in subsequent pregnancies, dysmenorrhea and abnormal uterine bleeding. It tends to be associated with poor uterine wound healing after CS.<sup>6</sup> Methods regarding the closure of the

uterine incision should be noted with benefits and potential hazards in order to provide the best surgical procedure for women undergoing CS. Closure technique and mechanical pull is the most important thing affecting the surgical wound. Therefore, a new method designed, the purse-string double-layer uterine closure (Turan technique) compared with conventional techniques, and then compare the incidence of postoperative scar defect as a short-term result and long term complications. Turan technique shows a different technique than classical double-layer uterine closure, where there is a decreased incidence of cesarean scar defect and the mechanical stress in the area around the uterine incision. High mechanical pressure on lower uterine segment will interfere with perfusion and oxygenation, where oxygen is an essential factor for a wound healing process.<sup>5</sup>

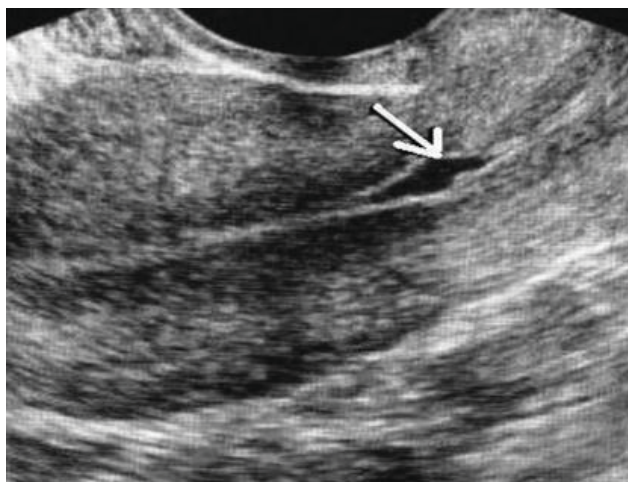## Turan Technique Procedure

Turan technique in Turkish research begins with Pfannenstiel abdominal incision and Kerr technique for uterine incision. Uterine closure begins from one corner of the incision and then the uterine incision wound is closure using Poliglactin 910 number 1 thread 1. The first layer transversely passes the inner line of the myometrium and the second layer transversely passes the outline of the myometrium- visceral peritoneum, which then followed by the purse string method. Next, the Poliglactin back to the beginning and tied with a knot. By using a purse-string double-layer closure, the aperture in the centre of the uterine incision will be added with a single figure of eight stitches. Uterine exteriorization and peritonealization as well as rectus muscle and subdermal spaces are also performed on this technique. Each patient received a 1-gram intravenous Cefazolin prophylactic antibiotic, and the patient was able to return home three days after surgery.<sup>6</sup>

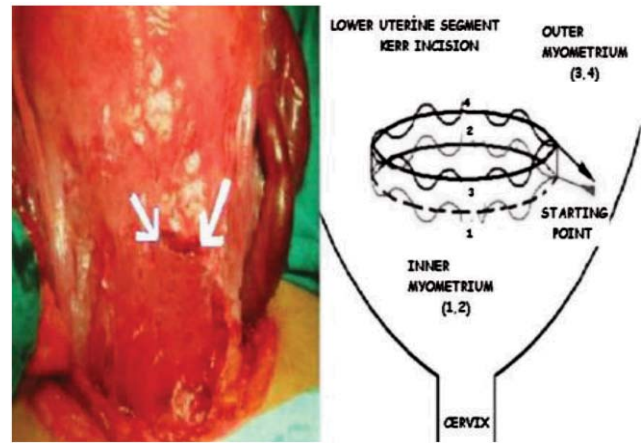


**Figure 1.** Conventional technique (arrow shows edge of the uterine incision)<sup>6</sup>

In order to evaluate cesarean scar defect with Turan technique can be performed using transvaginal ultrasonography at six weeks post-cesarean delivery with high transducer frequency (5-6 Mhz). The uterine dimension as well as the occurrence of intracavity, parametrial, and subvesical hematoma are assessed. The length of the incision is measured by a transversal axis. The integrity of the incision closure is assessed with transverse and longitudinal axis. The wedge shaped anatomical distortion in scar tissue of the uterine incision definite as uterine scar defect. Evaluation is also performed on the length of the defect.<sup>6</sup>



**Figure 3.** Cesarean scar defect by transvaginal ultrasonography (arrow shows uterine scar defect)<sup>7</sup>



**Figure 2.** Turan technique (arrow shows edge of uterine incision)<sup>6</sup>

### Research Evidence related Turan Technique

Based on research Turan technique can be an alternative closure method of the uterine incision. The mechanical tension at lower uterine segmen will decrease and then provide minimal incision defect. The length of the incision closure also becomes shorter when compared to conventional techniques. Turan technique is able to dramatically decrease cesarean scar defect.<sup>6</sup> The potential benefits of shorter scars of the Turan closure technique have not been widely studied. This is a natural consequence of the purse-string double-layer closure method. This method can change the anatomy of the lower segment for two reasons. First, segments can become narrower. The length of the incision before the closure is about 12 cm and then to 8.5 cm and 3.7 cm after the usual closing technique and Turan closure technique. Second, the Turan method pulls the tissue around uterine incision closure, which can change the structure of local anatomy. The combination of these two points explains the reduction of incidence postpartum uterine scar defect in the short term<sup>6,7</sup>

**Table 1.** Turan Technique Compare with Conventional Technique<sup>6</sup>

	Study group (n = 51)	Control group (n = 65)	P-value
Operation time (min)	28.5 ± 10.6	27.9 ± 4.8	0.177§
Length of uterine incision before suturing (cm)	12.0 ± 1.9	12.3 ± 2.3	0.361‡
Length of uterine incision after suturing (cm)	3.7 ± 0.9	8.5 ± 1.7	<0.001‡
No. of patients who needed additional sutures	14 (27.5%)	28 (43.1%)	0.02†
Duration of hospital stay (days)	2.5 ± 0.6	2.5 ± 0.5	0.919‡
Preoperative hemoglobin value (g/dL)	11.6 ± 1.1	11.5 ± 1.4	0.854‡
Postoperative 1st day hemoglobin value (g/dL)	11.3 ± 1.2	11.3 ± 1.5	0.825‡
Postoperative 6th week hemoglobin value (g/dL)	10.4 ± 1.3	10.3 ± 1.5	0.817‡

Bolding indicates statistical significance. † $\chi^2$ -Test, independent samples Student's *t*-test, §Mann-Whitney *U*-test.

Similar with study showed better results associated with bleeding control, Turan technique was able to reduce blood loss during CS procedures without having to use additional sutures compared to conventional techniques (27.5% vs 47.1%). This shows the superiority of this technique in terms of hemostasis.<sup>8</sup> For long-term results, more research is still needed. The results are promising because of the 10 patients who followed none of whom had complications.<sup>6</sup> Reported a significantly lower incidence of

cesarean scar defect in patients undergoing cesarean section with Turan technique (23.5%) than the double layer uterine closure technique (60%). Uterine incisional defects or cesarean scar defect are an etiologic factor of postoperative pelvic adhesion, placenta previa and accreta, uterine rupture, ectopic pregnancy of the uterine scar, abnormal uterine bleeding and dysmenorrhea. This means that a decrease incidence of uterine incisional defects is critical thing to prevent cesarean-related complications.<sup>6</sup>

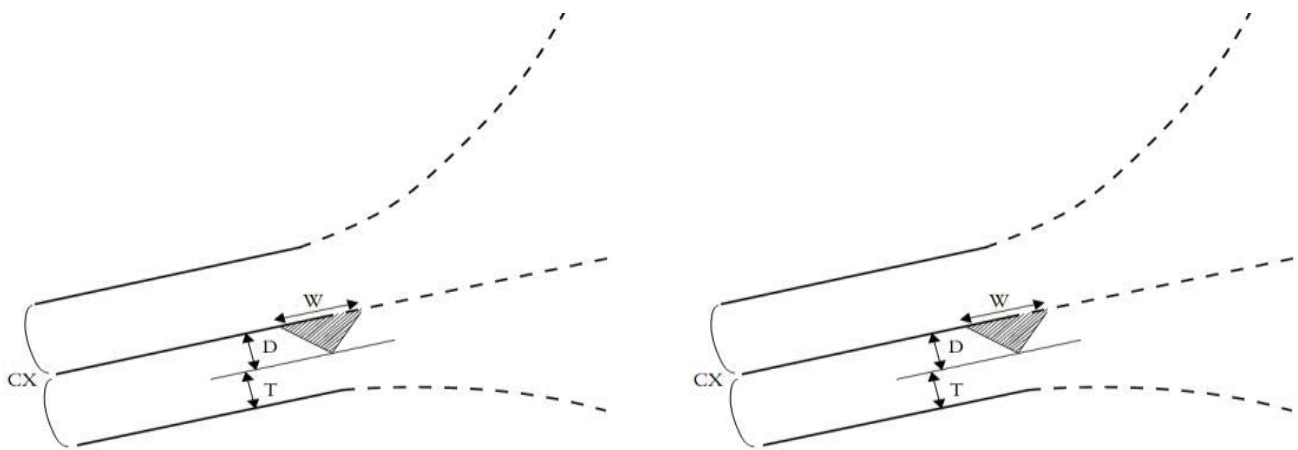
**Table 2.** Comparison of Ultrasound Evaluation at 6 weeks Postoperation<sup>6</sup>

	Study group (n=51)	Control group (n=51)	<i>t</i>	d.f.	<i>P</i>	95% CI	
						Lower	Upper
Uterine incision length (mm)	21.41 ± 4.38	26.28 ± 6.11	4.793	114	0.0001	2.854	6.876
Height of uterine incision defect (mm)	3.62 ± 1.19	4.06 ± 1.43	1.053	21.678	0.304	-0.424	1.297
No. of patients with uterine incision defect	12	39			0.0001 ( $\chi^2 = 15.429$ , d.f. = 1)		

Bolding indicates statistical significance. CI, confidence interval; d.f., degrees of freedom.

In 51 patients in the study group (suturing the uterine incision with Turan technique) and 65 patients in the control group were collected 6 weeks postoperative for transvaginal ultrasound examination, it was found that the length uterine incision closure was shorter in the study group ( $p = 0.0001$ , 95% IK = 2,854-6,876). Significantly, the number of patients with cesarean scar Defect was 12 (23.5%) in the study group and 39 in the control group (76.5%) with  $p = 0.0001$ . CSSH (Contrast Saline Sonohysterography) is a technique in which the saline fluid inserted into the uterine cavity using a hysteroinjector. CSSH combined with three dimensional ultrasonography provides several advantages over conventional sonography and can be used to detect cesarean scar defect. However, there was no clinical trials compare these two methods. Due to its simple, non-invasive and low-cost tool, transvaginal sonography remains the tool of choice for cesarean scar defect assessment.

In a recent study, a transvaginal ultrasound is a cesarean scar defect evaluation method that has a 100% sensitivity and very specific.<sup>9</sup> Another way to use CSSH is the Gel Instillation Sonohysterography (GIS) technique, which has the advantage of making the cervical filling more stable and reducing the discomfort for the patient while performing the procedure. Both CSSH and GIS can provide better imaging the edge of scar and the injury appears larger.<sup>10</sup> Research on cesarean scar defect has increased over the past few years and has been widely published. A variety of ways to detect and measure it has been widely described. Until now, there has been no consensus or standardization for detecting and measuring cesarean scar defect. Besides, there is an interest in the relationship between CSD and other gynecological symptoms, as well as the mechanisms behind the development of these symptoms.<sup>11</sup>



**Figure 4.** Cesarean scar defect measurement<sup>12</sup>

Cesarean scar defect is hypoechogenic area of lower uterine segment previous CS incision wound with a minimum depth of 1 mm. The measurement technique using TVS with the following measurement criteria.

**Table 3.** Cesarean Scar Defect Measurement Criteria

Size measurement criteria	
Scar defect width :	>5 mm
Scar defect depth:	>1 mm
Residual myometrial thickness :	>3 mm
Total thickness	2+4
Ratio depth/total thickness :	>50 %

Cesarean scar defect involves myometrial discontinuous at the site of a previous CS. These anatomical defects resulting from previous CS have been reported with clinical symptoms. Transvaginal ultrasound is highly accurate in detecting such defects.<sup>10</sup>

**Table 4.** Parameter Obtained by Multiple Logistic Regression Analyses of Uterine Position, History of Multiple CS and Scar Defect in Prediction on Clinical Symptom<sup>10</sup>

	$\beta$ (SE)	Wald $\chi^2$	P-value	OR (95%CI)
Postmenstrual bleeding				
Anteflexed or retroflexed uterus	-0.35 (0.44)	0.62	0.43	0.70 (0.30-1.68)
History of multiple CS	0.003 (0.34)	0	0.99	1.00 (0.51-1.97)
Defect width	0.23 (0.06)	15.65	<0.05	1.26 (1.12-1.41)
Dysmenorrhea				
Anteflexed or retroflexed uterus	-0.63 (0.43)	2.08	0.15	0.54 (0.23-1.25)
History of multiple CS	0.78 (0.34)	5.27	<0.05	2.18 (1.12-4.25)
Defect width	0.19 (0.05)	14.07	<0.05	1.21 (1.10-1.34)
Chronic pelvic pain				
Anteflexed or retroflexed uterus	-0.17 (0.45)	0.15	0.70	0.84 (0.35-2.01)
History of multiple CS	0.46 (0.37)	1.52	0.22	1.58 (0.76-3.28)
Defect width	0.25 (0.05)	22.47	<0.05	1.29 (1.16-1.43)

Multiple cesarean section and retroflexed uteri are risk factors for larger cesarean scar defects. The size of cesarean scar defect is associated with postmenstrual spotting, dysmenorrhea and chronic pelvic pain<sup>10-12</sup>

## CONCLUSION

Turan technique is a new suturing technique method on CS. This technique can be alternative because provide to reduce the incision closure length, better to control bleeding and reduce the incidence of the uterine scar tissue defect. Turan technique uses a purse-string double-layer closure method associated with low cesarean scar defect incidence at six weeks postoperative using transvaginal ultrasonography.

**REFERENCES**

1. Yazicioglu F, Gokdogan A, Kelekci S, Aygün M, Savan K. Incomplete Healing of the Uterine Incision After Cesarean Section: Is It Preventable? *Eur J Obstet Gynecol Reprod Biol.* 2010 ; 124: 32-3.
2. Dodd JM, Anderson ER, Gates S. Surgical Techniques for Uterine Incision and Uterine Closure at the Time of Cesarean Section. *Cochrane Database Syst Rev.* 2011;(3): CD004732.
3. Wilkinson C, Enkin MW. Absorbable Staples for Uterine Incisional Cesarean Section. *Cochrane Database Syst Rev.* 2009; (3):CD000005.
4. Van Dongen P, Nijhuis J, Jongsma H. Reduced Bloodloss During Cesarean Section Due to a Controlled Stapling Technique. *Eur J Obstet Gynecol Reprod Biol.* 2009; 32: 95–102.
5. Ofili-Yebovi D, Ben Nagi J, Sawyer E, Yazbek J, Lee C, Gonzalez J, Jurkovic D. Deficient Low-Segment Cesarean Section Scars: Prevalence and Risk Factors. *Ultrasound Obstet Gynecol.* 2011;31: 72–7.
6. Turan C, Esra Esim B, Aylin Onan Yilmaz, Yasemin Karageyim Karsidag, Meltem Pirimoglu. Purse-String Double-Layer Closure: A Novel Technique for Repairing the Uterine Incision During Cesarean Section. *J Obstet Gynecol.* 2015 ; 41(4): 565-74.
7. Matsubara S, Lefor AK, Ohkuchi A. Purse-String Double-Layer Closure for Cesarean Incision (Turan technique): Some Concerns. *J Obstet Gynecol.* 2015 ; 41(5): 828-9.
8. Lee JH, Cho DH. Myomectomy Using Purse String Suture During Cesarean Section. *Arch Gynecol Obstet.* 2011; 283: 35-7.
9. Verma U, Chanda M, Nagrath A, Singh S, Agrawal R. Assessment of Cesarean Section Scar Strength: Still A Challenge? *Ind J Clin Pract.* 2014 ; 24(10): 974-7.
10. Wang CB, Chiu WW, Lee CY, Sun YL, Lin YH, Tseng CJ. Cesarean Scar Defect: Correlation Between Cesarean Section Number, Defect Size, Clinical Symptoms and Uterine Position. *Ultrasound Obstet Gynecol.* 2009 ; 34: 85–9.
11. Marwa E, Helal O. Transvaginal ultrasonographic assessment of post-caesarean section Scar defects. *Med J Cairo Univ.* 2014 ; 82:39-44.
12. Vaate BD, Voet VD, Naji O, Witmer M, Veersema S, Brolmann HAM et al. Prevalence, potential risk factors for development and symptoms related to the presence of uterine niches following Cesarean section: systematic review. *Ultrasound Obstet Gynecol.* 2014;43: 372-82.