

Case Series

## Cryotherapy versus Cold Coagulation for Treating Cervical Precancerous Lesions

### *Krioterapi versus Cold Coagulation untuk Menatalaksana Lesi Prakanker Serviks*

Laila Nuranna, Nesyah Fatahan, Alfu Laily

Department Obstetrics and Gynecology  
Faculty of Medicine Universitas Indonesia  
Dr. Cipto Mangunkusumo General Hospital  
Jakarta

#### Abstract

**Objective :** Elaborating the results and comparison of cryotherapy and cold coagulation for cervical pre-cancer lesion cases in West Cakung Primary Health Center, Jakarta, Indonesia.

**Methods :** Observation was conducted from cervical pre-cancer lesion cases which were found by visual inspection with acetic acid (VIA) method. Those cases were directed into cryotherapy or cold coagulation based on randomization sampling. After 6-months post-therapy, the lesions were assessed. This study was administered on Cakung Barat Health Center, Jakarta, Indonesia, on April-December 2018. Of 10 cases, five were treated using cryotherapy and the rest with cold coagulation.

**Results :** After six months follow up, 1 of 5 patients from each therapy still had VIA positive result. The side effect in form of spotting after 1 month of cryotherapy and cold coagulation were 1/5 and 3/5, respectively. There were no other side effects reported during the 6-months follow up for both treatments.

**Conclusions :** The result of both treatments are relatively the same in converting VIA positive into negative, proved with each therapy have turned 4 for 5 patients with prior VIA positive into negative. The side effects endured by respondents were minimal in 1-month post-therapy, while there were no significant side effects after six months post-therapy.

**Keywords :** cervix, cold coagulation, cryotherapy, precancer lesion.

#### Abstrak

**Tujuan :** Memberikan informasi hasil terapi dan perbandingan antara krioterapi dan cold coagulation pada kasus lesi prakanker serviks dan efek samping yang ditimbulkan pada responden di wilayah puskesmas Cakung Barat, Jakarta, Indonesia.

**Metode :** Penelitian bersifat observasi pada beberapa kasus lesi prakanker serviks yang ditemukan dengan pemeriksaan inspeksi visual dengan asam asetat (IVA). Lesi tersebut diterapi dengan krioterapi atau cold coagulation secara acak. Setelah 6 bulan setelah terapi, lesi diperiksa ulang. Penelitian berlangsung di wilayah Puskesmas Kelurahan Cakung Barat, Jakarta, Indonesia pada bulan April – Desember 2018. Total kasus yang dinilai berjumlah 10 kasus dengan pembagian 5 kasus diterapi krioterapi, 5 kasus diterapi cold coagulation.

**Hasil :** Setelah 6 bulan pascapengobatan, 1 dari 5 pasien 1 dari 5 orang yang diterapi krioterapi atau cold coagulation dinyatakan masih IVA positif. Efek samping pengobatan setelah 1 bulan adalah spotting sebesar 1/5 dan 3/5, masing-masing. Tidak ada efek samping yang dikeluhkan pasien setelah 6 bulan pasca pengobatan krioterapi dan cold coagulation.

**Kesimpulan :** Hasil terapi lesi prakanker serviks dengan krioterapi atau cold coagulation relatif sama, hal ini dibuktikan dengan masing-masing terapi telah mengubah 4 dari 5 pasien dengan IVA positif menjadi IVA negatif. Efek samping minimal dirasakan responden pada 1 bulan pasca pengobatan, sedangkan tidak ada efek samping yang dirasakan setelah 6 bulan pengobatan pascaterapi.

**Kata kunci :** serviks, cold coagulation, krioterapi, lesi prakanker serviks.

**Correspondence author :** Laila Nuranna; lailaril@yahoo.com

**INTRODUCTION**

Data of GLOBOCAN, International Agency for Research on Cancer (IARC) on 2018 revealed that the number of incident and mortality of cervical cancer ranked in fourth position on women cancer globally.<sup>1</sup>In Indonesia this position become the second, after breast cancer.<sup>2</sup>

Cervical cancer caused by the Human Papilloma Virus (HPV) infection sub-type oncogenic.<sup>3</sup>The efforts to prevent cervical cancer could be administered in the early stages of HPV infection. Several methods are available to help the diagnosing of HPV infections in pre-cancer lesion stages; visual inspection with acetic acid (VIA), pap smear test, HPV DNA test and others.<sup>4</sup>If compared with pap smear or HPV DNA test, VIA method are more likely used in limited and low-resource setting like primary health center or other private first level of health facilities since it require minimum source of human resource and do not require comprehensive laboratory.<sup>5,6</sup>

After early detection, further therapy is needed if lesion found. One of the treatments is cryotherapy which has been included in cervical cancer early detection Indonesian national agenda through See and Treat program. In high-income countries, the incidence and mortality of cervical cancer decreased until 75% from early detection and lesion treatment before invasive cancer developed.<sup>7</sup>If single visit treatment were done, the potential incidence of cervical would be decreased by 26% more.<sup>8</sup>

On the Indonesian See and Treat program the roughest challenge is about the procurement of CO<sub>2</sub> or N<sub>2</sub>O gas.<sup>4</sup>Thus similar method like cold coagulation could be used to tackle this challenge, since it require electricity instead of gas. Cold coagulation therapy were adopted in many countries like Asia and Africa for its relatively simple features.<sup>4</sup>But in Indonesia; cold coagulation method are the least popular compared to cryotherapy. Therefore, a study to assess and compare the result of both treatments is needed. This study fulfills those aspects in comparing the result of VIA after treatments.

**CASE**

Among 5 of 10 patients received pre cancer lesion treatment of cryotherapy and the rest received cold coagulation based on randomization sampling. Their age average was 28 years old. All of patients were diagnosed with VIA positive and 3 of them has cervicitis (treatment: 2 cryotherapy and 1 cold coagulation). Cryotherapy technique was conducted with 3 minutes double freeze – 5 minutes rest between, while cold coagulation technique use single heater for 1 minute. After those treatments, patients were asked for 1 month sex abstinence and should do the follow up on 1 and 6-month post therapy.

Patient 1, 2 and 3 were diagnosed with VIA positive but no cervicitis and treated with cryotherapy. There were no significant side effects after treatment. The ice remaining were found 1 month post therapy and 6-months post treatment the remaining were not visible and VIA result turn into negative. Patient 4 and 5 were diagnosed with VIA positive and cervicitis and treated with cryotherapy. Spotting were detected just in patient 4 on 1-month post therapy 5. After 6 months, patient 4 and 5 reported that no side effects occurred and the VIA turn into negative, while patients 5 still has VIA positive with no cervicitis.

Patient 6, 7, 9, 10 were diagnosed with VIA positive, no cervicitis and treated with cold coagulation. Patient 6 and 9 reported no side effects endured while patient 7 and 10 has spotting in the first month and disappeared after. One of them were still diagnosed with VIA positive on 6 months post therapy. Patients 8 with VIA positive and cervicitis were also treated with cold coagulation. Spotting were occurred in the first month and disappeared after. The result after 6 month were both negative for VIA and cervicitis.

**Table 1.** Treatment, Result and Side Effects

Case	Age (year)	VIA Diagnosis	Treatment	Result (6 months post)	Side Effect (1 month post)	Side Effect (6 month post)
1	36	Positive	Cryotherapy	Negative	Watery discharge	No
2	44	Positive	Cryotherapy	Negative	Watery discharge	No
3	36	Positive	Cryotherapy	Negative	Watery discharge	No
4	33	Positive, Cervicitis	Cryotherapy	Negative, Cervicitis (-)	Watery discharge, Spotting	No
5	22	Positive, Cervicitis	Cryotherapy	Positive, Cervicitis (-)	Watery discharge	No
6	25	Positive	Cold Coagulation	Negative	No	No
7	27	Positive	Cold Coagulation	Negative	Spotting	No
8	43	Positive, Cervicitis	Cold Coagulation	Negative, Cervicitis (-)	Spotting	No
9	23	Positive	Cold Coagulation	Positive	No	No
10	30	Positive	Cold Coagulation	Negative	Spotting	No

## DISCUSSION

As this study, cryotherapy and cold coagulation were focused to treat cervical cancer pre-cancer lesion and cervicitis. Since 1964, cryotherapy has been used to cure chronic cervicitis and precancer lesion, while cold coagulation begin 2 years after it.<sup>9</sup> Cryotherapy use  $N_2O$  gas since it colder than  $CO_2$  gas (freezing poin of  $-89^\circ C$  compared to  $-78^\circ C$ ), while cold coagulation use electricity.<sup>10</sup> The objective of these abrasive treatment are to freeze the transformation zone. Thus cellular necrosis affects the development of pre cancer lesion.






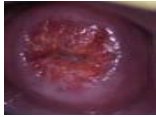
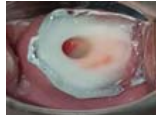
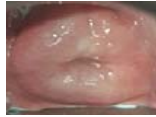


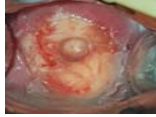

The success rate in this study were 80% in resolving VIA positive both using cryotherapy and cold coagulation. This finding is coherence with the study from India about effectivity of cryotherapy in precancer lesion which revealed the almost 80% clearance confirmed by biopsy histology on Cervical Intraepithelial lesion (CIN).<sup>11</sup> On 2014 the effectivity of cold coagulation with the 94% success rate on CIN 1-3.<sup>12</sup>

Complication and significant side effects were not likely occurred in this study. The safety of cryotherapy were reported through study from India and coagulation from Brazil.<sup>11,13</sup> Both studies highlighted that the minimal side effects happened after treatment, including abdominal cramp, heat sensation and spotting. In this study, all patient with cryotherapy were reporting watery discharge as general side effect after treatment with cryotherapy and 1 of them also were reporting spotting during 1 month post therapy.











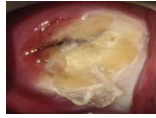
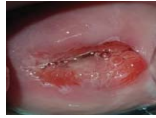
Excision methods Loop Electrosurgical Excision Procedure (LEEP), Large Loop Excision Transformation Zone (LLETZ), laser conization, and cold knife conization) are highly efficacious than ablative treatment (cryotherapy and cold coagulation). Unfortunately, they are unsuitable for low-level providers and remote areas, higher risk of complications, and quite costly.

In Indonesia, as a nation with separated island and do not have enough obgyn in every area, ablative treatment is a solution for treat patient with lesion of cervical cancer. See and treat program is an national program combination between community screening with VIA examination and treat with cryotherapy. In the implementation, Cryotherapy has minimum side effects and the simplicity tools so can be used by well-trained general practioner or midwife. However, in the process, the constrain of cryotherapy is the availability of gas ( $N_2O$  or  $CO_2$ ) especially for transport the gas to isolated area. Other than that, gas could block the duct which resulting in temperature inconsistency.<sup>14</sup> So, there is needed the alternative methods which has same usability and can answer the challenges.

**Table 2.** Cervix Documentation on Patients with Cryotherapy

No. Patient	Pre IVA	Post IVA	Post Cryotherapy	Post 6 month treatment
1				
3				
5				

**Table 3.** Cervix Documentation on Patients with Cold Coagulation

No. Patient	Pre IVA	Post IVA	Post Cold Coagulation	Post 6 months treatment
6				
8				
10				

Another affordable alternative method to treat precancer lesion and cervicitis and similarities in the implementation likes cryotherapy is cold coagulation.<sup>4</sup> The tool used generates heat from electric energy to destroy the lesion in cervical tissue: the superficial epithelium disappears after treatment, and the destruction of stroma and glandular due to drying.<sup>15</sup> The duration of treatment were about 30-60 seconds.

The cold coagulation therapy is relatively easy to perform, requiring only the small device and electricity. With all the convenience provided by cold coagulation method, the dependency of electrical source might become the shortfall. Temperature and optimum application has been not determined yet in consensus to assess the Depth of Necrosis (DON). A research of 80 patients stated that the average of necrosis depth after single application with flat tip were 2,6 mm (100°C for 20 seconds) until 3,5 mm (120°C for 30 seconds).<sup>16</sup> Compared with cryotherapy, the

average of necrosis depth after a double freeze technique a 3-min freeze followed by a 5-min thaw and a 3-min freeze is similar.<sup>17</sup> The pain generated during the procedure of cold coagulation should be noted. Further study should be administered to determine the parameter for optimum therapy and the tolerance of the patients.

In this study, 1 of 5 patients with cryotherapy or cold coagulation was reported pregnant until 3-4 months post therapy. The review from WHO stated that abortus rate on patients with cryotherapy is not likely higher than the common population.<sup>18</sup> Another study also stated that cold coagulation has no effect on fertility, proven by 94% women were pregnant during 2 year post therapy.<sup>19</sup>

Cold coagulation are currently not included in WHO 2013 cervical cancer treatment guideline for its limited source of study material. While this treatment gained popularity in some low and

middle income countries (LMICs) during the rising abrasive treatment in Asia and Africa countries for its simplicity features, cold coagulation were slowly replaced by *Loop* Electrosurgical Excision Procedure (LEEP).<sup>4</sup> Therefore, this study aimed to add the information about the effectivity and safety of cold coagulation if compared with cryotherapy.

### CONCLUSION

The results of cervical precancer lesion treatment with cryotherapy or cold coagulation were relatively same in converting VIA positive to VIA negative, both 4 of 5 patients in every treatment were recovered. The side effects on both therapy after 1 month were minimal only spotting were reported. While after 6 months therapy, there were no side effects reported.

### ACKNOWLEDGMENT

This study was supported by the Faculty of Medicine Universitas Indonesia and Dr. Cipto Mangunkusumo Hospital. We would like to thank our colleagues from the Division of Gynecologic Oncology for providing input and further expertise for this study. The authors did not receive any specific grant from any funding agency in the public, commercial, or nonprofit sectors.

### REFERENCES

1. Freddie B Jacques F, Isabelle et al. Global Cancer Statistics: GLOBOCAN Estimates of Incidence and Mortality Worldwide for 36 Cancers in 185 Countries. American Cancer Society CA: Cancer J Clin. 2018;68:394-424
2. International Agency for Research on Cancer Indonesia. Globocan. 2018
3. Andrijono. Kanker Serviks, Divisi Onkologi Departemen Obstetri dan Ginekologi. Jakarta : Fakultas Kedokteran Universitas Indonesia. 2007: 25-6.
4. Mauricio Maza, Celina M. Schocken, Katherine L. Bergman, Thomas C. Randall, Miriam L. Cremer. Cervical Precancer Treatment in Low- and Middle-Income Countries:A Technology Overview. J Glob Oncol. 2017; 3(4): 400-8
5. N. Laila, Donny N B, Purwoto G, Winarto G, Utami T.G. Anggraeni T.D et.al,. Prevalence, Age Distribution, and Risk Factors of Visual Inspection With Acetic Acid-Positive From 2007 to 2011 in Jakarta. J Cancer Prev.2017; 22 (2): 103-7
6. Sankaranarayanan R, Budukh AM, Rajkumar R. Effective screening programmes for cervical cancer in low- and middle-income developing countries. Bull World Health Organ. 2001;79(10):954-62.
7. Ferlay J, Shin HR, Bray F, et al. Estimates of worldwide burden of cancer in 2008: GLOBOCAN. Int J Cancer.2008; 127(12):2893-917.
8. Goldie SJ et al. Policy analysis of cervical cancer screening strategies in low-resource settings. Clinical benefits and cost effectiveness. Journal of the American Medical Association, 2001, 285: 3107-3115.
9. Mauricio Maza, Celina M. Schocken, Katherine L. Bergman, Thomas C. Randall, Miriam L. Cremer.2016. Cervical Precancer Treatment in Low- and Middle-Income Countries:A Technology Overview. American Society of Clinical Oncology. jgo.ascopubs.org 2893-2917, 2010
10. Cooper SM, Dawber RP: The history of cryosurgery. J R Soc Med 94:196-201, 2001
11. Cremer M, Ditzian L, Winkler JL, et al: Comparison of depth of necrosis using cryotherapy by gas and number of freeze cycles. J Low Genit Tract Dis 19:1-6, 2015
12. Sankaranarayanan R, Rajkumar R, Esmey PO, Fayette JM, Shanthakumary S, Frappart L, et al. Effectiveness, safety and acceptability of 'see and treat' with cryotherapy by nurses in a cervical screening study in India. Br J Cancer 2007;96(5):738-43.
13. Dolman L, Sauvaget C, Muwonge R, et al: Meta-analysis of the efficacy of cold coagulation as a treatment method for cervical intraepithelial neoplasia: A systematic review. BJOG 121:929-942, 2014
14. Ashrafun Nessa, Paolo Naud, et al. . Efficacy, Safety, and Acceptability of Thermal Coagulation to Treat Cervical Intraepithelial Neoplasia: Pooled Data From Bangladesh, Brazil and India. J Clin Gynecol Obstet. 2017;6(3-4):58-64
15. Santos CL, Torres J, Sanchez J, et al: Lack of effectiveness of CO2 cryotherapy for treatment of CIN. Int J Gynaecol Obstet 87:44-45, 2004
16. Semm K: New apparatus for the "cold-coagulation" of benign cervical lesions.AmJ Obstet Gynecol 95:963-966, 1966
17. Duncan ID: Cold coagulation. Baillieres Clin Obstet Gynaecol 9:145-155, 1995
18. WHO : WHO Guidelines : Use of Cryotherapy for Cervical Intraepithelial Neoplasia. Geneva, Switzerland,WHO Press, 2011
19. WHO: WHO Guidelines: Use of Cryotherapy for Cervical Intraepithelial Neoplasia. Geneva, Switzerland, World Health Organization, 2011. Int J Gynaecol Obstet 118:97-102, 2012